

Digital panoramic radiograph about positions of maxillary posterior tooth roots to maxillary sinus floor

Aprillia Dian Pertiwi*, Ria Noerianingsih Firman*, Farina Pramanik*

*Department of Dentomaxillofacial Radiology, Faculty of Dentistry Universitas Padjadjaran

ABSTRACT

Introduction: Maxillary sinus floor is part of the alveolar bone adjacent to the apex of the posterior maxillary teeth that often causes complications in dentistry. Their anatomical relationship can be obtained by panoramic radiograph. The purpose of this study was to describe the position of maxillary posterior teeth's root towards maxillary sinus floor using digital panoramic radiograph. **Methods:** Research method is descriptive with purposive sampling technique for archives of patient's digital panoramic radiograph in Radiography Installation from January to March 2016. **Results:** 88 samples were obtained from 207 digital panoramic radiographs archives. The result showed that type 3 was dominated by P1 (86.8% right, 88.2% left), type 2 is dominated by P2 (24.7% right, 21% left), type 1 is dominated by M2 in the right (31.2%) and M1 in the left (38.1%). The most commonly found was type 3. **Conclusions:** Topographically, the inferior wall of maxillary sinus has the greatest distance to the root apex of tooth in the first premolar area with the largest cortical bone thickness. While the molar area, especially the second molar has the shortest distance. Based on age, type 1 were found on the age group of > 49 years; type 2 were found in the age group 40-49 years; type 3 were found in the age group 30-39 years, 40-49 years and > 49 years. Based on the gender, in all the teeth (premolars and molars) type 1 and type 2 is more prevalent in males, whereas type 3 mostly found in women.

Keywords: digital panoramic radiograph, maxillary posterior teeth, maxillary sinus floor

INTRODUCTION

The maxillary sinus is a pyramid-shaped airspace and known as the largest sinus which located on both sides of the maxilla. The maxillary sinus floor is a part of the alveolar bone tends to be close to the apex of the maxillary posterior teeth with different spaces.¹ Based on research conducted by Ok (2014) against the population of the Turkish people using the radiograph Cone-Beam Computed

Tomography (CBCT), the first and second maxillary premolars tend not to relate to the maxillary sinus floor as compared with the first and second molar. Around 63.4-67.6% of second molar's root was penetrated into maxillary sinus which shows the percentage of the posterior teeth is larger than others. No significant difference was found between the left and right side, but the difference was found on gender and age variables. Tooth root penetration into the maxillary sinus floor is more

Corresponding author: Ria Noerianingsih Firman, Department of Dentomaxillofacial Radiology, Faculty of Dentistry Universitas Padjadjaran, Indonesia. Jalan Sekeloa Selatan I, Bandung, West Java, Indonesia, 40132.

prevalent in men than women and the prevalence tends to decrease along the increase number of age. The roots of the molar teeth which penetrated into the maxillary sinus has found and increased on the first, second and third decade. The study also found that the molar root penetration into the maxillary sinus has increases after the age of 60 years.²

The correlation between maxillary sinus and root of posterior teeth become one of the reason of the complication occurrence of maxillary sinus during the treatment, including extraction that can lead to the formation of oroantral communication. If it becomes chronic, it will cause sinusitis maxillaris. Root canal treatment procedure can cause perforation to maxillary sinus so the dental material will reach into maxillary sinus. Orlay (1966) in Ok (2014)² reported the occurrence of extrusion of root canal sealer N2 into the maxillary sinus while doing the obturation procedure, caused a heavy pain in trigeminal area and *Aspergillois sinus* ^{2,3}

A deep understanding of the anatomical relationship between the apex of the maxillary posterior teeth and the maxillary sinus is a crucial thing for an operator. This can help to avoid or minimize the complication after extraction or root canal treatment.^{2,4}

The description of the anatomical relationship between the posterior maxillary teeth roots and the maxillary sinus floor can be obtained through panoramic radiography. Panoramic radiography is an extraoral radiography that relatively fast and easy to used, especially by the general practitioner. Panoramic radiography is able to interpret the facial structure of the maxillary and mandible dental arch and its supporting structure. The maxillary sinus is usually have a good visualization through panoramic radiograph.⁵

METHODS

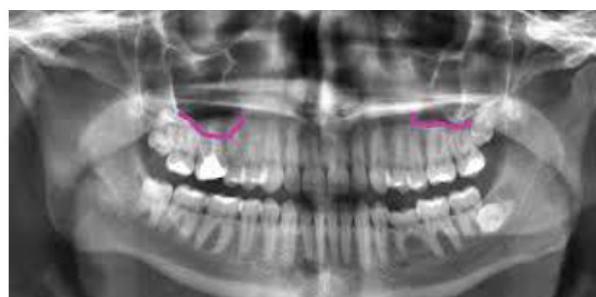The method of the research was a descriptive using method of the survey. The population used in this study is taken from the archives of the panoramic radiograph that provides an overview of the maxilla and mandible and its surrounding structures and stored digitally in Installation Radiology RSGM Universitas Padjadjaran in the period of March 2016 with total 207 radiograph.

The sample of the research done by purposive sampling technique based on inclusion criteria include: the panoramic radiograph in good quality and ideal; the posterior maxillary permanent teeth with apical root which has been closed or the formation of teeth's root perfectly without any pathological condition on both of the regio (right and left); the panoramic radiograph patients showed a good maxillary sinus condition, characterized by a thin cortical bone radiography which is visible as a smooth, thin, and continous radioopak line.

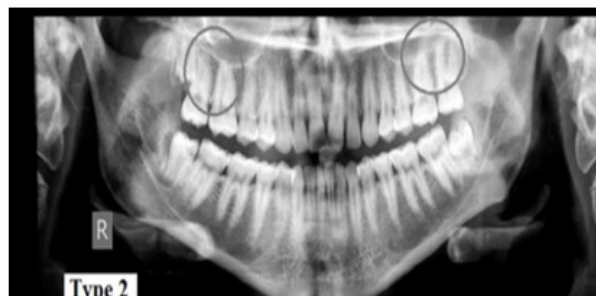In addition, the selection of the sample is done by considering the exclusion criteria periapical abscesses, cysts, periapical granuloma, condensing osteitis, hypersemen-tosis, sclerotic bone, periodontal disorders, sinus approximation. After the selection is done according with the criteria of the required samples, it has been elected 88 panoramic radiographs as objects of research.

The position of the posterior maxillary teeth roots against maxillary sinus floor was the location of the root apical posterior maxillary permanent teeth against the maxillary sinus floor. If the tooth has more than one root, it is seen as the nearest root apical teeth to maxillary sinus floor in two dimensions. The posterior maxillary teeth which being examined is the teeth with apical root which has experienced the closure perfectly is characterized by the absence of radiolusent area limited in apex, there is a thin and clear line of radiolusent around the root, the root is not a funnel-shaped, the root canal is clearly visible from the pulp chamber until the apical root and the apical foramen has opened.

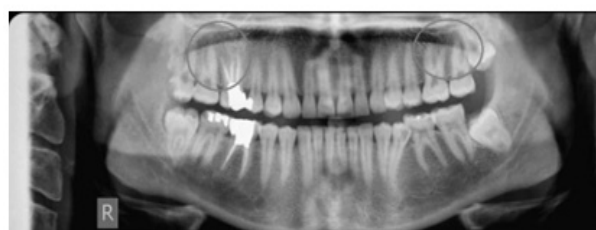
The position of the posterior maxillary teeth roots against the maxillary sinus floor is grouped by the classification which stated by Ok.² If the root apical penetrated into the maxillary sinus floor and lamina dura and periodontal membrane are not visible on the superimposition description of the tooth root with maxillary sinus, it will be classified as the type 1 position (fig. 1). If apical root contacts with the maxillary sinus floor, it will be classified as a type 2 position (fig. 2). If apical root is below the maxillary sinus floor which the lamina dura and periodontal membrane looked as intake at superimposition description of root teeth with the maxillary sinus, then it will be



A



B



C

Figure 1. A. Type 1. The penetration of apeks into maxillary sinus at the right side; B. Type 2 The apex contacted into the maxillary sinus floor; C. Type 3. The apex is below the maxillary sinus floor.⁶

classified in a type 3 position (Fig. 3). Overall, the number of female gender's radiograph are about 53 radiographs, while males's radiograph are about 35 radiographs.

RESULTS

Table 1 shows maxillary posterior tooth root's position towards the maxillary sinus floor. Based on the table, it shows that the type 3 (root is below the maxillary sinus floor) happens most on the first premolar, either at right region (86.8%) and at left region (88.2%). The type 2 (the root is contacted to the maxillary sinus floor) is dominated by second premolars, both at the right region (24.7%) and at the left region (21%).

Table I. The position of the posterior maxillary teeth roots toward the maxillary sinus floor in general

| Regio | Gigi | T1 | | T2 | | T3 | |
|--------|------|----|------|----|------|-----|------|
| | | n | % | n | % | n | % |
| I | P1 | 1 | 1.3 | 9 | 11.8 | 66 | 86.8 |
| | P2 | 5 | 6.2 | 20 | 24.7 | 56 | 69.1 |
| | M1 | 25 | 29.8 | 6 | 7.1 | 53 | 63.1 |
| | M2 | 24 | 31.2 | 9 | 11.7 | 44 | 57.1 |
| | M3 | 9 | 15.0 | 8 | 13.3 | 43 | 71.7 |
| Total: | | 64 | | 52 | | 262 | |
| II | P1 | 1 | 1.3 | 8 | 10.5 | 67 | 88.2 |
| | P2 | 5 | 6.2 | 17 | 21.0 | 59 | 72.8 |
| | M1 | 32 | 38.1 | 3 | 3.6 | 49 | 58.3 |
| | M2 | 15 | 19.5 | 13 | 16.9 | 49 | 63.6 |
| | M3 | 9 | 15.0 | 5 | 8.3 | 46 | 76.7 |
| Total: | | 62 | | 46 | | 270 | |

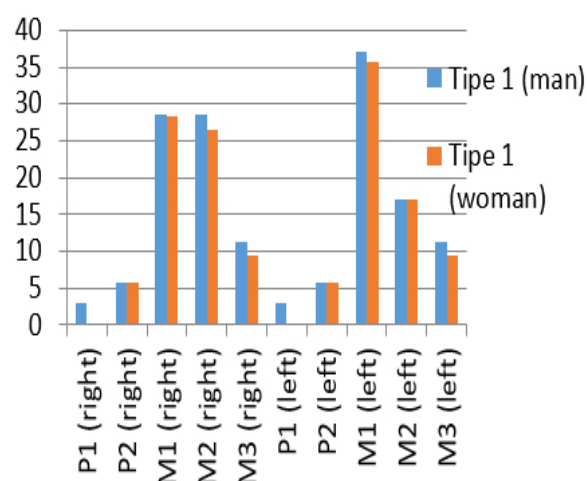


Figure 1. The distribution of maxillary posterior tooth root's position (type 1) frequent against the maxillary sinus floor based on gender

Type 1 (the root penetrates into the maxillary sinus floor) shows the difference between the left and right of the region. The type 1 at the right region dominated by second molar (31.2%), whereas in the left region dominated by the first molar (38.1%).

Based on age, the type 1 most often occurs on the fifth decade (at 100% of the M1 from the total number of M1 on the age group); type 2 is much going on its fourth decade (in M3 of 100% of total M3 on the age group); many of type 3 occur

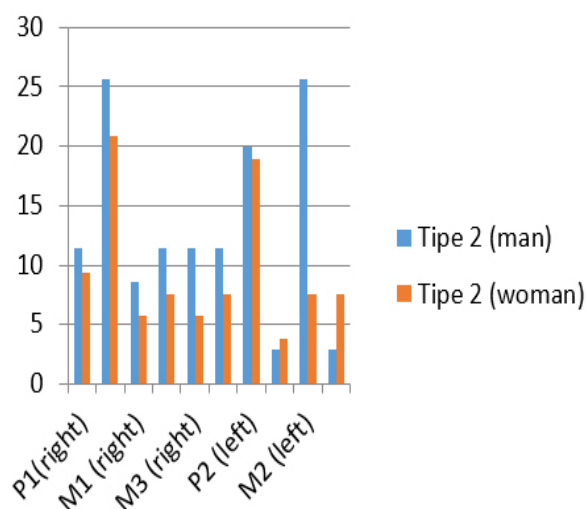


Figure 2. The distribution of maxillary posterior tooth root's position (type 2) frequent against the maxillary sinus floor based on gender.

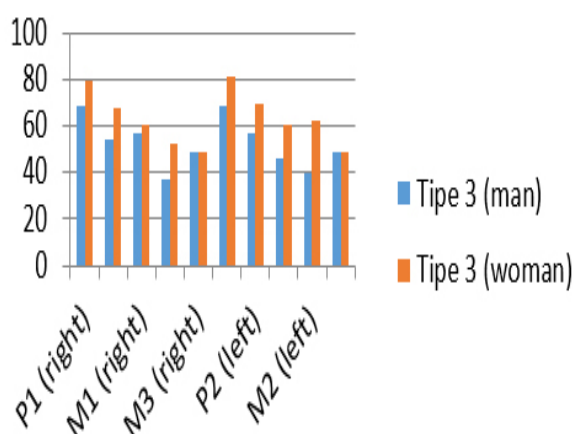


Figure 3. The distribution of maxillary posterior tooth root's position (type 3) frequent against the maxillary sinus floor based on gender

in the decade of the third, fourth, and fifth (at P1, P2, M3 amounted to 100% of the total amount of each tooth on the age group).

Based on gender, type 1 and 2 positions are dominated by men (Fig. 1 and 2), while the position of the type 3 are dominated by women (Fig. 3).

DISCUSSION

Based on Table 1 which presents the overall results of the study, the maxillary first premolars showed the greatest percentage for type 3 (86.8%

and 88.2%) and least for type 1 (1.3%). The results of this study in accordance with the results of previous research suggests that the maxillary first premolars is not penetrated into the maxillary sinus floor.⁴

Different with the first premolar, maxillary second premolars have the frequency distribution of type 1 (6.2%) and type 2 (24.7% and 21%). The results of this study in accordance with similar research conducted by Ok (2014) towards the data from CBCT from 849 patients with the 5166 of premolar teeth and 2486 of maxillary molar teeth.²

Based on the result of the study on table 1, type 1 is dominated by the first molar (38.1%) in left region. This is in accordance with the research of Arabion *et al.*⁶ which concluded that the root of the maxillary first molar is nearer to the maxillary sinus floor than the second molar. OK² stated same statements that type 1 is found at the root of maxillary first molar teeth.

Besides that, Huang *et al.*⁷ case reports also stated that the root of the maxillary first molar has a higher risk of perforation to maxillary sinus than another maxillary posterior teeth related to anatomy and morphology of the maxillary sinus. However in the right region, type 1 is dominated by the second molar for about 31.2%.⁷ This is in accordance with similar research conducted by Hassan⁴ and Shokri⁸ which States that the penetration of the posterior maxillary teeth against the maxillary sinus floor is dominated by the second and first molar.

According to Kwak⁹ in his research towards the population of Korea society, the findings above can occur due to anatomically, the topography of the inferior wall of the maxillary sinus has the farthest distance towards the apex in the first premolars area with cortical bone thickness. The apex of the maxillary second premolars have a distance closer to the maxillary sinus if is compared with first premolars. While molar area, especially the second molar has the shortest distance.

The first left molar is 0.1-0.52 mm against the maxillary sinus floor. The second molar on the left region is 0.31-0.78 mm against the maxillary sinus floor. In other words, the first molar on the left region has a close distance with the maxillary sinus than second molar. Whereas the first molar on the right region is a 0.7-1.86 mm against the maxillary sinus floor, the second molar is 0.25-1.06

mm against the maxillary sinus floor. On the right region, the second molar has a closer distance with the maxillary sinus than the first molar.

Age is being one of the factors that influence the relationship between maxillary posterior teeth's apex and the maxillary sinus floor related with the pneumatization of maxillary sinus.^{4,10} The maxillary sinus began to form from the intrauterine stage. The growth continues rapidly until the age of 3 and then slows down. The growth of the sinus will be back quickly at the age of 7 and continued until the 4-5 years later. The pneumatization of maxillary sinus progresses most rapidly between the ages of 7-12 years and reach maximum size at the age of 18.¹²

Based on the age group, the type 1 is mostly occurred on the fifth decade. This can happen because at this age group, almost all of the samples that have been examined, suffered a loss of one or more of the posterior teeth. According to Malik¹¹, the maxillary sinus will extend to processus alveolaris which was left after the loss of one or more of the maxillary posterior teeth. A wide pneumatization occurred after loses second molar teeth or extraction of more than one maxillary posterior teeth.^{11,12}

After the loss of teeth, the Schneiderian periosteum membrane shows an increase in the activity of the osteoclasts which caused the resorption of sinus floor and resulted the expansion of the maxillary sinus. The side of the maxillary sinus which having the greatest expansion was at the sinus floor because this side have associated with the teeth. The extraction or tooth loss in this area will cause an increasing in pressure or functional force. Processus alveolaris depends on the mandible teeth are there or not, regardless of whether the teeth still active doing a mastication or not. The process of bone apposition decreases as a result of the loss of functional stimulation.¹³

The type 2 mostly occurred in four decades, while type 3 mostly occurred in the decade of the third, fourth, and fifth. This finding is in accordance with the results of previous studies which concluded that the prevalence of tooth penetration into the maxillary sinus floor tends to decrease along the increasing of age. This can occur because the average distance of maxillary posterior teeth's apex against the limit

of maxillary sinus floor will grow in the line with increasing number of age.

Overall, the difference between the left and right regions is caused by the difference in size of the maxillary sinus. Research conducted by Mattar *et al.*¹⁶ found significant differences between the relationship of the maxillary posterior teeth root against the maxillary sinus floor in the left and right region. According to him, although it is small, the human maxillary sinus is asymmetric.¹⁴

If it is reviewed based on gender, type 1 and type 2 mostly happened on men, the type 3 mostly found in women. These findings are similar with previous research done by Ok² who discovered the existence of frequency distribution variation on each type of gender. The research was supported by the theory that stated that the length and height of the maxillary sinus on men was larger than women.¹⁵

The men need a larger respiratory tract to support organs and muscles which is relatively larger, start from the nose and nasopharynx. Thus, the physiological changes in the size and shape of the nasal cavity is a direct result of the respiratory needs and the maxillary sinus is a cavity which located in the complex of nasomaxillaris.¹⁶ In addition, the growth of the maxillary sinus continued until the third decade on the men and women in the second decade. Therefore, the size of the maxillary sinus on men is larger than on women will cause a closer relationship between the apex of maxillary posterior teeth towards the maxillary sinus floor.

CONCLUSION

Topographically, the inferior wall of maxillary sinus has the greatest distance to the root apex of tooth in the first premolar area with the largest cortical bone thickness. While the molar area, especially the second molar has the shortest distance. Based on age, type 1 were found on the age group of >49 years; type 2 were found in the age group 40-49 years; type 3 were found in the age group 30-39 years, 40-49 years and >49 years. Based on the gender, in all the teeth (premolars and molars) type 1 and type 2 is more prevalent in males, whereas type 3 mostly found in women.

REFERENCES

1. Chandra S, Chandra S, Chandra M, Chandra N. Textbook of dental and oral histology with embryology. New Delhi: Jaypee Brothers Medical Publisher; 2004. p. 267.
2. Ok E, Gungor E, Colak M, Altunsoy M, Nur BG, Aglarci OS. Evaluation of relationship between the maxillary posterior teeth and the sinus floor using cone-beam computed tomography. 2014;36:907-14.
3. Borgonovo AE, Berardinelli FV, Favale M, Maiorana C. Surgical options in oroantral fistula treatment. Open Dentist J 2012;6: 94-8.
4. Hassan BA. Reliability of periapical radiographs and orthopantomograms in detection of tooth root protrusion in the maxillary sinus: correlation results with cone beam computed tomography. J Oral Maxillofac Res 2010;1(1):1-7.
5. White SC, Pharoah MJ. Oral radiology principles and interpretation. 6th ed. Missouri: Mosby Elsevier; 2009. p. 175,188.
6. Arabion, Hamidreza, Abdol AH, Yasamin SA, Reyhaneh E, Reza T. Comparison of the distances between the maxillary sinus floor and root-tips of the first and second maxillary molar teeth using panoramic radiography among dolichocephalic and brachycephalic and mesocephalic individuals. JDMT 2015;4(2):81-8.
7. Huang IY, Chen CM, Chuang FH. Caldwell-luc procedure for retrieval of displaced root in the maxillary sinus. Oral Surg Oral Med Oral Pathol Oral Radiol Endod 2011;112(6): 59-63.
8. ShokriA, Lari S, Yousef F, Hashemi L. Assessment of the relationship between the maxillary sinus floor and maxillary posterior teeth roots using cone beam computed tomography. J Contemp Dent Pract 2014;15(5):618-22.
9. Kwak HH, Park HD, Yoon HR, Kang MK, Koh KS, Kim HJ. Topographic anatomy of the inferior wall of maxillary sinus in Koreans. Int J Oral Maxillofac Surg 2004;33(4):382-8.
10. Newman, Takei, Klokkevold, Carranza. Carranza's clinical periodontology. 12th ed. Missouri: Saunders Elsevier; 2015. p. 560.
11. Malik, Neelima Anil. Textbook of oral and maxillofacial surgery. New Delhi: Jaypee Brothers Medical Publisher. 2008. p. 563-7, 569-671.
12. Sharan, Arbel dan David Madjar. Maxillary sinus pneumatization following extraction: a radiographic study. Int J Oral and Maxillofacial Implants 2008;23(1):48-56.
13. Son HJ, Jang Y L, Hyoun CK, Il HP, Sang C L. The volumetric changes of the maxillary sinus according to missing the maxillary posterior teeth: A study using computed tomography.
14. Essam M, Hammad L, Faden A, Khalil H. Relation of maxillary teeth to the maxillary sinus in normal saudi individuals living in riyadh. Bioscie Biotech Res Asia 2010; 7(2):695-700.
15. Teke HY, Duran S, Canturk N, Canturk G. Determination of gender by measuring the size of the maxillary sinuses in compute-rized tomography scans. Surg Radiol Anat 2007;29: 9-13.
16. Ahmed M, Asilah Y, Rozita H. A three dimensional computed tomography (3D-CT): A study of maxillary sinus in malays. CJBAS 2013;01:125-34.