

## **Oral manifestations and their management in children undergoing haemodialysis treatment**

**Arléte Suzy Puspa Pertiwi, Inne Suhera Sasmita, Meirina Gartika**

**Department of Pediatric Dentistry Faculty of Dentistry Universitas Padjadjaran**

### **ABSTRACT**

Haemodialysis is a medical procedure that artificially filters blood. This procedure is carried out to treat children with end-stage renal disease (ESRD). Although haemodialysis is a lifesaving treatment, it also raises many severe oral manifestations associated with ESRD. Among these are increased hypoplasia, enamel opacities, uremic stomatitis, oral bleeding, increased periodontal disease, reduced salivary flow, xerostomia, and an increased tendency of calculus deposition. This paper will discuss the oral manifestations associated with ESRD and their management in children undergoing haemodialysis treatment.

**Key words:** Oral manifestation, management, haemodialysis, ESRD, children

### **INTRODUCTION**

The prevalence of children with chronic renal disease is increasing worldwide. But the advances in pediatric nephrology during the last two decades have resulted in a marked increase in the number of children surviving from this disease. Although many complications of this disease can now be prevented or treated, these therapeutic advances have introduced new problems, including the concerns of oral health.<sup>1</sup>

Renal or kidneys are two bean-shaped organ located toward the back of the body on either side of the spine near the waistline. They are about the size of a fist and protected by other organs and two of the lower ribs. The function of the renal are cleaning the blood and removing waste products, balancing water and salt to control fluid in the body, controlling blood pressure, helping to make red blood cells and build strong bones,

and controlling the amount of potassium, calcium, magnesium, and phosphorus in the blood.<sup>2</sup>

Impairment of renal function may lead to a disease called renal failure which further divided in to acute and chronic renal failure. Acute renal failure (ARF) is characterized by the abrupt of the renal to regulate water and electrolyte homeostasis. ARF is encountered in 3 to 10 percent of all admissions to neonatal intensive care units. It is a life-threatening, abrupt reduction of urinary output to less than 300 mL/m<sup>2</sup> per day that is precipitated by prolonged renal ischemia in most cases. In childhood if ARF is due to hemolytic-uremic syndrome, postinfectious acute glomerulonephritis, of dehydration are reversible, but a small percentage may progress to chronic renal failure (CRF).<sup>3</sup>

CRF is defined as a progressive decline in renal function associated with a reduced glomerular filtration rate.<sup>4</sup> CRF may be the result



of slowly progressive kidney disease and seldom is fully reversible. The most common causes are diabetes mellitus, glomerulonephritis, and chronic hypertension. In childhood CRF is associated with obstructive uropathy, congenital aplastic, hypoplastic, and dysplastic kidneys.<sup>3,4</sup> CRF affects nearly 500/1 million populations per year. One to two percent is in the pediatric age range.<sup>3</sup> Patients with CRF who could not be treated need to follow renal replacement therapy by dialysis or transplantation, and the disease is then referred to as end-stage renal disease (ESRD).<sup>1</sup>

Haemodialysis is a medical procedure that artificially filters blood. This procedure was carried out to treat children with ESRD. Patients who do not respond to aggressive medical management, dialysis is an option. It was performed in a dialysis center of the hospital by trained health care professionals. The child will be connected to a large haemodialysis machine that drains the blood, bathes it in a special dialysate solution to remove waste substances and fluids, then returns it to the bloodstream. Haemodialysis is usually done several times a week and for four to five hours.<sup>2,5</sup>

As a consequence of CRF and its treatment, a number of oro-dental changes occur that persist after the end-stage is reached. This paper will discuss about the oral manifestations associated with CRF and ESRD and their management in children undergoing haemodialysis treatment.

### Oral and dental aspects

CRF can give rise to wide spectrum of oral manifestations, affecting the hard or soft tissues of the mouth.<sup>5</sup> There are number of reports on the oral changes in patients with CRF and ESRD. Among these are enamel hypoplasia, enamel opacities, uremic stomatitis, oral bleeding, decreased periodontal disease, reduced salivary flow, xerostomia, and an increased tendency for calculus deposition.<sup>1</sup> Dental changes are dependent on the time of onset of the disease. Renal failure is also associated with a reduced prevalence of caries due to the inhibitory effect of increased salivary urea level.<sup>1,6,7</sup> Children with CRF usually exhibit growth retardation. Delayed eruption of permanent teeth has been reported.<sup>4,6</sup>

### Enamel hypoplasia

An early effect in dentition is enamel hypoplasia due to a defect in enamel development and mineralization.<sup>7</sup> Those teeth calcification during renal failure will exhibit chronological hypoplasia or hypomineralization. Enamel hypoplasia occur in the primary and permanent teeth with or without brown discoloration (Fig. 1). Teeth are often green or brown because of the incorporation of blood products such as haemosiderin and biliverdin.<sup>4,6,7</sup>

The position and extent of the defect indicate the timing, duration and to some extent the severity of the underlying metabolic upset.

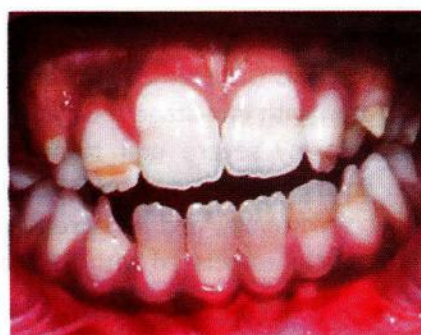

Figure 1. Moderately severe enamel hypoplasia.<sup>7</sup>

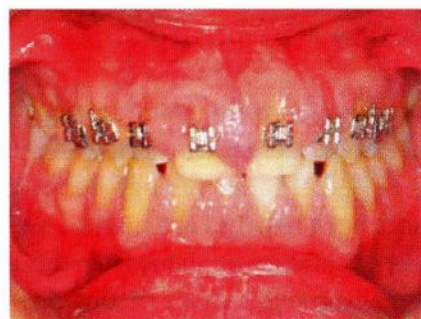

Figure 2. Gingival enlargement associated with drug therapy.<sup>7</sup>

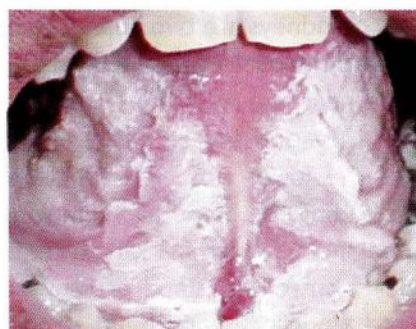


Figure 3. Uremic stomatitis.<sup>7</sup>



Enamel hypoplasia has been attributed to the production of poorly-formed enamel as a result of ameloblast disruption. Factors responsible for this disruption include hypocalcaemia, decreased serum levels of 1,25-dihydroxycholecalciferol, and raised serum levels of inorganic phosphate and serum parathyroid hormone. An elevated serum fluoride level, causing fluorosis, may be an etiological factor in the development of enamel defects in children with CRF, since kidneys have an important function in the removal of inorganic fluoride from the body.<sup>7</sup>

Enamel hypoplasia is usually reparable to a high aesthetic standard using dental composite filling material to improve appearance. Children and adolescents become increasingly aware of their appearance as they mature, so the request for an improvement in appearance may come in the early years of the second decade of life.<sup>7</sup>

### **Gingival enlargement**

Gingival enlargement secondary to drug therapy is reported as mostly oral manifestation of renal disease. Of greater importance is the prevalence of gingival enlargement due to interstitial enlargement in response to cyclosporine A, nifedipine, and/or calcium channel blockers. It principally affects the labial interdental papillae, although it can become extensive, involving the gingival margins, lingual and palatal surfaces Fig.2.<sup>4,7</sup>

Another factor associated with the development of gingival hyperplasia is inadequate oral hygiene and plaque accumulation. The gingival enlargement rarely responds to increased oral hygiene measures alone. This is because the change in gingival architecture makes it virtually impossible to clean adequately. Once a good standard of oral hygiene has been obtained, gingival reduction is carried out using a combination of conventional cutting and electrosurgery. Dental plaque control is achieved by the use of 0.2% chlorhexidine gluconate mouthwash twice a day for two minutes.<sup>7</sup>

### **Oral bleeding**

Children on dialysis are anticoagulated or may have platelet dysfunction. These may lead to a bleeding tendency due to capillary fragility and thrombocytopenia. Any treatment, and especially

extractions, should be performed the day after dialysis. Sockets should be packed and sutured. Antibiotic prophylaxis is highly required.<sup>6</sup>

### **Uremic stomatitis**

Uremic stomatitis is a rarely reported oral mucosal disorder possibly associated with longstanding uremia in CRF patients.<sup>8</sup> Uremic stomatitis may develop when serum urea is over 300 mg/mL.<sup>6</sup> This disorder seen mostly in cases of undiagnosed and untreated CRF, so the incidence will decrease if patients undergo haemodialysis.<sup>9</sup>

Uremic stomatitis occurs as ulcerated or nonulcerative forms.<sup>6</sup> Painful plaques and crusts are distributed predominantly on the buccal mucosa, the floor of dorsum of the tongue, and the floor of the mouth.<sup>9</sup> Uremic stomatitis is first described as a red mucosa covered with a pseudomembrane (Fig. 3), may respond to treatment of underlying renal failure. Symptomatic treatment is peroxide mouthwash.<sup>8</sup>

### **Oral malodor**

Uremic patients may have an ammonia-like oral odor, which occurs in about one-third of children receiving haemodialysis. CRF can give rise to altered taste sensation, and some patients complain of an unpleasant and/or metallic taste or a sensation of an enlarged tongue.<sup>4</sup>

### **Xerostomia**

Symptoms of xerostomia can arise in many individuals receiving haemodialysis. Possible causes include restricted fluid intake, side effects of drug therapy, and/or mouth breathing. Longterm xerostomia may predispose to caries and gingival inflammation and can give rise to difficulties in speech, mastications, dysphagia, sore mouth, and loss of taste. It also predisposes to caries and infections such as candidiasis and acute suppurative sialadenitis.<sup>4</sup>

### **Dental management**

Untreated dental infections can potentially contribute to morbidity. There is a need for detailed assessment and provision of good dental care following the diagnosis of CRF. Regular clinical review is important for the early identification of oral complications of renal disease.<sup>4</sup> Consultation

with renal physician is the most important thing before managing oro-dental complications. Preventive efforts are of great importance. Extraction of pulpally involved teeth. Treatment should be aggressive with antibiotic prophylaxis.<sup>6</sup>

## CONCLUSION

Prevalence of CRF is increasing worldwide. This may lead to a number of children who undergone haemodialysis as one of many treatments option for CRF. Oral and systemic complications can occur as a result of CRF and its treatment. Dental management of patients is complicated by some systemic consequences, thus it has to be carried out under professional supervision. The use of well-supervised treatment protocols will lead to effective and safe dental management of children with CRF who undergoing haemodialysis.

## REFERENCES

1. Ertugrul F, Cigdem E, Ertugrul S, Sevgi M. The oral health status of children undergoing hemodialysis treatment. *Turkish J Pediatr* 2003;45:108-13.
2. Wenderfer S. Kidneys' function. [cited 2006 Jul 4]. Available from: [www.ped1.med.uth.tmc.edu](http://www.ped1.med.uth.tmc.edu).
3. Chan JCM, Debra MW, Karl SR. Kidney failure in infants and children. *Pediatrics in Review* 2002;23(2):47-59.
4. Proctor R, Kumar N, Stein A. Oral and dental aspects of chronic renal failure. *J Dent Res* 2005;84(3):199-208.
5. Wallace MS. Critical care of the acute renal failure patient. [cited 2006 Jul 4]. Available from: [www.vetlatran.com.htm](http://www.vetlatran.com.htm).
6. Cameron AC, Widmer RP. *Handbook of pediatric dentistry*. 2<sup>nd</sup> ed. Sydney: CV Mosby; 2003. p. 260-2.
7. Lucas VS, Roberts GJ. Oro-dental health in children with chronic renal failure and after transplantation. A clinical review. *Pediatr Nephrol* 2005;20:1388-94.
8. Leao JC, Gueiros LAM, Segundo AVL. Uremic stomatitis in chronic renal failure. *Clinics* 2005;60(3):259-62.
9. Long RG, Hlousek L, Doyle JL. Oral manifestations of systemic disease. *Mount Sinai J* 1998;65(5,6):309-15.