

# **The measurement of the alveolar bone crest in aggressive periodontitis using Cone Beam Computed Tomography imaging**

**Astia Dwiputri Lestari\*, Azhari\*, Sri Wendari\*\***

**\*Department of Dentomaxillofacial Radiology Faculty of Dentistry Universitas Padjadjaran**

**\*\*Department of Periodontics Faculty of Dentistry Universitas Padjadjaran**

## **ABSTRACT**

The normal alveolar bone crest located at a distance of 1 to 2 mm from CEJ towards the apical. If there is a bone loss, the alveolar bone crest located at 2 mm more to the apical from CEJ. The alveolar bone loss is one characteristic of aggressive periodontitis and the onset of the disease at the age of puberty. The purpose of this research was to know and to assess the height of alveolar bone crest using Cone Beam Computed Tomography (CBCT) in patients with aggressive periodontitis. The type of this research was descriptive. A total of 317 sample CBCT imagery from 6 aggressive periodontitis patients. The result of this research showed that average height of alveolar bone crest second premolar distal, the first molar mesial, first molar distal and second molar mesial on the first region were 3 mm, 4.2 mm, 6.1 mm, and 4.8 mm respectively. On the second region were 3.2 mm, 3.6 mm, 3.6 mm, and 3.4 mm respectively, and in the third region were 2.4 mm, 2.8 mm, 2.5 mm dan 1.4 mm consecutively. While in the fourth region were 2.9 mm, 3 mm, 2.8 mm, and 2.3 mm respectively. The average height of alveolar bone crest of aggressive periodontitis was 3.8 mm. Slicing CBCT imagery on coronal view for the anterior region and sagittal view for the posterior region, showed the characteristic of height alveolar bone crest was arch-shaped which showed the different height of alveolar bone crest of the second premolar distal until second molar mesial.

**Keywords:** Alveolar bone crest, bone loss, aggressive periodontitis, Cone Beam Computed Tomography (CBCT)

## **INTRODUCTION**

Dental problems were placed on the sixth of the highest diseases as reported by Indonesian National Household Health Survey. Two of the high prevalence diseases were caries and periodontal disease. Periodontal disease is the second major problems which considered as a problem in society.

Periodontal disease is an inflammation process of periodontal tissue which starts from an

invasion of microorganisms and its products into the gingiva. Inflammation from the supporting structures of the teeth caused by microorganisms resulted in progressive damage in periodontal ligament and alveolar bone by forming a pocket, gingival recession, or combination of both which called periodontitis.<sup>2</sup>

American Academy of Periodontology (AAP)<sup>8</sup> in 1999 described classifications of periodontal diseases and conditions, which were gingival disease,

chronic periodontitis, aggressive periodontitis, periodontitis as a manifestation of systemic disease, necrotizing periodontal disease, abscesses of the periodontium, periodontitis associated with endodontic lesions, and developmental or acquired deformities and conditions.<sup>2</sup> One of the periodontal diseases classification is aggressive periodontitis. Aggressive periodontitis usually happened in younger patients with lower prevalence compared to chronic periodontitis. Aggressive periodontitis epidemiology data in Indonesia has not existed, but there are several experiments about this prevalence.

One of the experiments that have done in the Periodontics Clinics of Faculty of Dentistry Universitas Airlangga discovered that there was an escalation from 9% in 1991 to 13% in 2002. In 2010, experiment regarding this disease was done by Nariratih in Student's Clinic of Faculty of Dentistry Universitas Padjadjaran from May-July 2010 showed that aggressive periodontitis prevalence was as much as 3,13%.<sup>2,3</sup>

Aggressive periodontitis is a continuation of gingival inflammation into a deeper periodontal tissue structure and alveolar bone crest. CEJ measurement of the alveolar bone crest was >2 mm (3-4mm) (Hodges, 1997). CEJ measurement of alveolar bone crest could differentiate stages of periodontal diseases. This could help when diagnosing periodontal diseases. The correct diagnosis is important for treatment planning. Diagnosis determined by a careful analysis of the case, clinical examination, and other examinations (radiography, blood test).<sup>2,4,5</sup>

Radiography has an important role in making a diagnosis of the periodontal disease. Radiography gives specific information about the condition of periodontal tissue and records about bone condition during the course of the disease, but conventional radiography has limits, one of them is it only showed the two-dimensional image in three-dimensional condition.<sup>6</sup>

Cone Beam Computed Tomography (CBCT) is the newest radiography equipment represents the maxillofacial area. CBCT shows an accurate image of the jaw, different from the panoramic picture. Because of the distortion in panoramic, it cannot relied on taking a measurement. Also, CBCT could deliver cross-sectional image (buccolingual), axial, coronal, sagittal, and panoramic. Meanwhile

the conventional panoramic can only produce one-dimensional image, which was mesiodistal or anteroposterior and there is also a superimpose image.<sup>7</sup>

There has not been any research performed in Faculty of Dentistry Universitas Padjadjaran observing the alveolar bone crest in aggressive periodontitis patient using CBCT imaging. Therefore, the purpose of this research was to discover and assess the alveolar bone crest in aggressive periodontitis patients using Cone Beam Computed Tomography (CBCT) Imaging.

## **METHODS**

The type of this research was descriptive and using a secondary data which was recorded in CBCT Radiography in Faculty of Dentistry Universitas Padjadjaran from May-July 2010 from the patient diagnosed clinically and radiographically as aggressive periodontitis.

Sampling was done by total sampling from 6 subject aggressive periodontitis's CBCT radiograph data, consisted of 321 images of a mesial-distal radiograph of alveolar bone crest CBCT imaging from aggressive periodontitis patient's alveolar bone fragments in each teeth interdental which were recorded in Faculty of Dentistry Universitas Padjadjaran from May-July 2010.

The variable of this research was the alveolar bone crest. The alveolar bone crest defined as the distance between cementoenamel junction (CEJ) to alveolar bone crest. The measurement was done by drawing a fictitious horizontal line from the alveolar bone crest to the mesial-distal of adjacent teeth, then a fictitious vertical line from CEJ to the horizontal of the alveolar bone crest.

Tools used in this research are Cone Beam Computed Tomography (CBCT) Radiograph and a computer. The computer used was an ASUS Notebook series A42J with Generic PnP Monitor, with software included the Microsoft® Office Word 2007, Microsoft® Excel 2007, and the Capture Screen Program.

The procedure of this research was after obtaining the secondary data of aggressive periodontitis patients with 3D CBCT in the Radiology Installation of Faculty of Dentistry Universitas Padjadjaran Dental Hospital; the EazyDent® program was opened then the patient's data were

chosen and opened with the EzImplant® program. After having the image in the monitor, the contrast was set by selecting windowing menu. The central axis pointer was moved to the interproximal teeth which the alveolar bone was seen, then zoomed. After having the right position, the attention was focused on the coronal and sagittal view. After the alveolar bone crest visible, a fictitious line was drawn using a ruler to get the alveolar bone crest's data, from the alveolar bone crest to the mesial-distal of adjacent teeth, then from CEJ to the horizontal of the alveolar bone crest. The data was then collected and presented using a table to be counted for the average value.

## RESULTS

This research was conducted in May 2011 in Faculty of Dentistry Universitas Padjadjaran Dental Hospital. From 6 3D Cone Beam Computed Tomography (CBCT) radiograph archives of aggressive periodontitis patient, 4 of it consisted of CBCT radiograph archives of localized aggressive periodontitis and 2 archives of generalized

aggressive periodontitis taken during May-July 2010, so the mesial-distal radiograph of alveolar bone crest in each tooth interdental from CBCT images obtained were 321 images.

The image results of the alveolar bone crest of the aggressive periodontitis patient that viewed from the coronal direction to see the anterior teeth and from the sagittal direction to see the posterior teeth were presented in Table 1-Table 3. Table 1 described the CBCT radiograph imaging of 37 teeth surface with the alveolar bone crest of  $\leq 2$  mm (11.52%), and 284 teeth surface with the alveolar bone crest of  $> 2$  mm (88.48%).

Figure 1 showed the alveolar bone crest height of aggressive periodontitis using CBCT imaging in anterior region (I1) and posterior region (M1). It can be seen that there were damage on the anterior region (I1) and posterior region (M1).

Table 2 showed the average alveolar bone crest height in anterior region was 4.08 mm, while in posterior region was 3.38 mm. This table also showed the average alveolar bone crest height of all aggressive periodontitis patient was 3.8 mm. The lowest alveolar bone crest height was found

Table 1. Percentage of mesial and distal tooth surface with the alveolar bone crest height of  $\leq 2$  mm and  $> 2$  mm

	Alveolar crest height				Total
	$\leq 2$ mm (n)	%	$> 2$ mm (n)	%	
Anterior (I1-I2)	5	5.31%	89	94.69 %	94
Anterior (C)	3	6.81%	41	93.13%	44
Posterior (P1-P2)	10	11.9%	84	88.1%	94
Posterior (M1)	4	10%	36	90%	40
Posterior (M2-M3)	15	30.61%	34	69.39%	49
<b>Total</b>	<b>37</b>	<b>11.52%</b>	<b>284</b>	<b>88.48%</b>	<b>321</b>

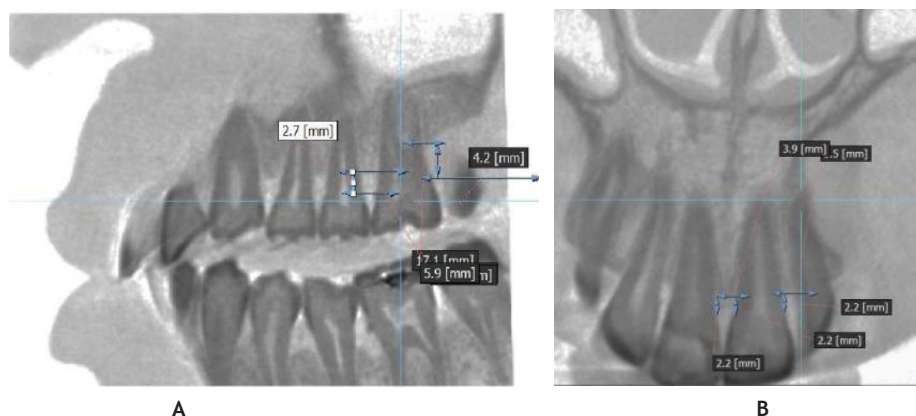


Figure 1. (A) Alveolar bone crest height of aggressive periodontitis patient in the anterior region (I1) using CBCT Imaging, (B). Alveolar bone crest height of aggressive periodontitis patient in the posterior region (M1) using CBCT Imaging.

Table 2 The average alveolar bone crest height (in mm) in the anterior region, posterior region, maxilla, and mandible

	Anterior (I1-I2)	Anterior (C)	Posterior (P1-P2)	Posterior (M1)	Posterior (M2-M3)	Average
Maxilla	4.65	3.75	3.21	4.31	4.52	4.08
Mandible	4.18	3.52	3.85	2.76	3.59	3.38
Average	4.39	3.72	3.05	4.07	3.78	
<b>Average</b>	<b>4.05</b>		<b>3.63</b>		<b>3.8</b>	

Table 3. The average alveolar bone crest height (in mm) in the mesial and distal aspects

Surfaces	P2					M1					M2				
	Region					Region					Region				
	1	2	3	4	Σ	1	2	3	4	Σ	1	2	3	4	Σ
Mesial	3.2	2.6	2.7	3.1	2.9	4.2	3.6	2.8	3.0	3.4	4.8	3.4	1.4	2.3	3
Distal	3.0	3.2	2.4	2.9	2.8	6.1	3.6	2.5	2.8	3.7	5.6	4.1	2	2.1	3.5

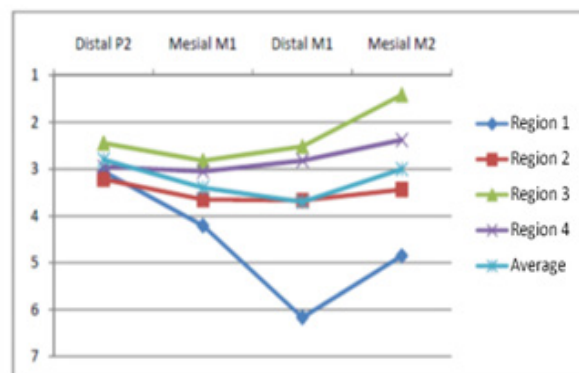


Figure 3. Arch-shaped pattern from the distal P2 to the mesial M2

in the anterior region (I1-I2), which was 4.39 mm and in the posterior region (M1) was 4.07 mm.

Table 3 showed the difference between the mesial-distal second premolar (P2) height and the second molar (M2). This difference will make an arch-shaped pattern of the bone damage that can be seen in Figure 2. The arch-shaped pattern was visible in the distal second premolar (P2) to the mesial second molar (M2) located in all four regions.

Figure 3 showed the arch-shaped pattern generated from the height difference of the average alveolar bone crest height between the distal second premolar, mesial first molar, distal first molar, and the mesial second molar in the all four region.

## DISCUSSION

Aggressive periodontitis is an infectious disease in the periodontal tissue with a two-

dimensional radiographical image of alveolar bone resorption that usually happened in the first molar and incisus tooth.<sup>8</sup> The higher distance from alveolar bone crest to CEJ was a proof of the bone loss. The higher the distance from CEJ to alveolar bone crest, the higher the alveolar bone loss, thus the lower alveolar bone crest. With bone loss, the height of the alveolar bone was 2mm closer towards the apical from CEJ (Langland, 2002). Such circumstances fit the results of CBCT imaging in 6 aggressive periodontitis patients with the lowest alveolar bone crest in the anterior region which was 4.39 mm (I1-I2). The localized state of periodontal tissue damage in molar and incisus caused by molar and incisus are the first erupted teeth.<sup>2</sup>

Results from the sample of CBCT imaging, aggressive periodontitis patients which having the alveolar bone crest of  $\leq 2$  mm was on the 37 teeth surface (11.52%), and as much as 284 teeth surface

were having the alveolar bone crest of  $>2$  mm (88.48%). This result was consistent with research conducted by Hodges in 1997, which stated that in the early periodontitis stage (in 1999 the term was changed into aggressive periodontitis), the distance from CEJ to the alveolar bone crest was  $>2$  mm. This condition happened due to a gingiva inflammatory progressivity towards the alveolar bone crest with deeper periodontal structure.<sup>4</sup>

The term “juvenile periodontitis” or “early periodontitis,” “prepubertal periodontitis” dan “rapidly progressive periodontitis” now are classified as aggressive periodontitis.<sup>9</sup> Early periodontitis described as gingiva inflammatory progressivity towards the alveolar bone crest with deeper periodontal structure, with a little loss of attachment and alveolar bone. The distance from CEJ to alveolar bone crest was 3-4 mm.<sup>4</sup> This circumstance matches with the result of CBCT imaging from 6 aggressive periodontitis patients that showed the average height of the aggressive periodontitis bone crest was 3.8 mm. The result of this study also showed that the maxillary alveolar bone crest height was lower than the mandible. The maxillary alveolar bone crest height was 4.08 mm, while the mandible was 3.38 mm. This condition can be caused by plaque and calculus accumulation, and more commonly occurred in the maxillary than the mandible. Another reason could be due to the thinner and less dense cortical in the maxillary than the mandible. That is why the maxillary alveolar bone was easier to come through the resorption than the mandible.<sup>10</sup>

The alveolar bone crest height of aggressive periodontitis was different in the anterior region and the posterior. The height in the anterior region was 4.05 mm while in the posterior region was 3.63 mm. This condition happened due to the thickness difference between the anterior and posterior region.<sup>11</sup> The defect pattern of the alveolar bone in aggressive periodontitis is arch-shaped.<sup>2</sup> This shape was seen from the result showed that the alveolar bone crest from distal second premolar to mesial second molar has a different height that will form an arch-shaped pattern.

## CONCLUSION

The slicing of the CBCT imagery on coronal view for the anterior region and sagittal view for

the posterior region, showed the characteristic of height alveolar bone crest was arch-shaped which showed the different height of alveolar bone crest of the second premolar distal until second molar mesial.

## REFERENCES

1. Tampubolon NS. Dampak Karies Gigi dan Penyakit Periodontal Terhadap Kualitas Hidup [dissertation]. Medan: USU; 2005.
2. Newman MG, Takei HH, Carranza FA. Carranza's Clinical Periodontology. 10th ed. Philadelphia: Saunders-Elsevier; 2006. p. 452-66, 506-12, 561-80.
3. Nariratih D, Rusyanti Y, Susanto A. Prevalence and characteristics of Aggressive Periodontitis. *Padjadjaran J Dent.* 2011;23(2):97-104.
4. Hodges K. Concepts in Nonsurgical Periodontal Therapy. 1st ed. New York: Delmar-Thomson Learning Inc.; 1998. p. 128-34.
5. Lindhe J, Lang NP, Karring T. Clinical Periodontology and Implant Dentistry. 2nd ed. Hoboken: Blackwell Publishing; 1990.
6. White SC, Pharoah MJ. Oral Radiology: Principles and Interpretation. 5th ed. St. Louis: Mosby-Elsevier; 2004. p. 314-24.
7. Oral Health Group [homepage on internet]. Toronto: Perschbacher S. 2009. Making The Most of Cone Beam CT Responsibly. [cited 2011 Apr]; [about 2 screens]. Available from: <https://www.oralhealthgroup.com/features/making-the-most-of-cone-beam-ct-responsibly/>
8. Grant DA, Stern IB, Listgarten MA. Early Onset Periodontitis (juvenile periodontitis/aggressive periodontitis). In: Eley BM, Soory M, Manson JD. Periodontics. 6th ed. St. Louis: Mosby-Elsevier; 2010. p. 377-97.
9. Armitage GC. Development of a classification system for periodontal diseases and conditions. *Ann Periodontol.* 1999 Dec;4(1):1-6.
10. Torkzaban P, Arabi B, Torkan R, Khoshhal M. Assessment of cemento-enamel junction-alveolar bone crest distance in interproximal areas of intact primary molars in healthy 7-9 year old boys in Hamadan. *Avicenna J Dent Res.* 2009;2(1):25-30.
11. Borges MS, Mucha JN. Bone density assessment for mini-implants positioning. *Dental Press J Orthod.* 2010 Nov-Dec;15(6):1-9.