

Correlation between mandibular bone density with CD4-T cells and duration of HAART in HIV-infected children

Intan Maulani¹, Risti Saptarini Primarti^{2*}, Irna Sufiawati³, Ratna Indriyanti², Niekla Survia Andiesta⁴, Eriska Riyanti²

¹Division of Paediatric Dentistry, Executive Polyclinics of Al-Ihsan Regional Public Hospital, Indonesia

²Department of Paediatric Dentistry, Faculty of Dentistry Universitas Padjadjaran, Indonesia

³Department of Oral Medicine, Faculty of Dentistry Universitas Padjadjaran, Indonesia

⁴Children and Community Oral Health Division, School of Dentistry of International Medical University, Malaysia

ABSTRACT

Introduction: Perinatal HIV infection has decreased adverse bone health effects and mineral accrual. HIV-infected patients have a multifactorial origin, including HIV bone cell infections, inflammatory cytokine effects on osteoblast and osteoclast activity, and HAART. The research objective was to analyze the correlation between the mandibular bone density with CD4 T-cells and duration of HAART in HIV-infected children. **Methods:** The mandibular bone density in the HIV-infected pediatric population was evaluated using a panoramic radiograph. The research design was a cross-sectional and univariate regression analysis for the sampling method. Mandibular density analysis using Spearman and Pearson correlation and HAART duration using Kendall correlation. Thirty-five HIV-infected children and seventeen non-HIV-infected children were recruited. **Results:** This study showed the significant correlation between Mandibular cortical shape index of HIV-infected and non-HIV children and there is a significant correlation between fractal dimension of HIV-infected and non-HIV children ($p < 0.05$). There is no significant correlation between mandibular bone density and the CD4 level ($p < 0.05$). Mandibular bone density and duration HAART and have a significant correlation ($p < 0.001$). This research showed correlations between mandibular bone density CD4 T-cells and duration of HAART in HIV-infected children. **Conclusion:** There is no correlation between the mandibular bone density and CD4 T-cells count, however, there is a correlation between the mandibular bone density and duration of HAART in HIV-infected children.

Keywords: HIV-infected children; mandibular bone density; CD4 T-cells; panoramic radiograph; HAART.

p-ISSN: 1979-0201; e-ISSN: 2549-6212; Available from: <http://jurnal.unpad.ac.id/pjd/article/view/15894>

DOI: [10.24198/pjd.vol33no1.15894](https://doi.org/10.24198/pjd.vol33no1.15894)

Submission: Feb 26, 2018; Accepted: Mar 30, 2021; Published online: Mar 31, 2021

*Corresponding author: Risti Saptarini Primarti, Department of Paediatric Dentistry, Faculty of Dentistry Universitas Padjadjaran, Indonesia. Jalan Sekeloa Selatan I, Bandung, West Java, Indonesia, 40132. Phone: +62 815-7000-890; e-mail: risti.saptarini@fkg.unpad.ac.id

INTRODUCTION

HIV infection has a major CD4 T-cells target of T-lymphocytes at CD4 receptors. The loss of cell function in HIV infection leads to a progressive immune response disorder. An overview of HIV infection is a decrease in CD4 T-cells, an increase in CD8 T-cells and chronic immune activation leading to immune system dysfunction. During untreated HIV infection, the homeostatic response of CD4 T-cells depletion occurs in an inflammatory environment, contributing to increased proliferation in CD4 cells and CD8 cells. Recovery of CD4 T-cells after antiretroviral therapy (HAART) is a slow process that usually takes years and depends on CD4 cell count before therapy.^{1,2,3}

Activation of T-cells products results in RANKL and inflammatory cytokines, all of which can induce RANKL expression in the osteoblasts in inflammatory and autoimmune cases. Some T-cells-derived cytokines such as IL-12 and IL-18 can mingle with RANK signalling, osteoclastogenesis and osteoclast function. The regulatory mechanisms that activate T-cells may inhibit the development of osteoclasts and interferon (IFN)- γ cytokines during the resistance to the virus. IFN- γ activates the osteoclast proteasome pathway resulting in TRAF6 degradation.^{1,2}

The effects of direct HIV infection on growth and bone mineralisation are given particular attention to children and adolescents because of the rapid decline in bone mass that occurs from infancy to early childhood. In addition, it is known that achieving a low peak bone mass at the end of adolescence may lead to an increased risk of osteoporosis and associated complications in subsequent life.^{4,5,6}

Mass changes in the cortical and trabecular regions affect bone strength caused by differences in mineral content that determine both regions' function. Trabecular has greater metabolic activity and more frequent mineral changes than cortical, thus predisposing bone mass deficiency.^{6,7} Previous research records the high BMD variation levels, as measured by quantitative computed tomography (QCT) in the mandible.⁸ Another alternative commonly used to assess the status of bone density is to use DEXA. The cortical bone of the inferior mandibular border is eroded by age and in patients with low bone BMD or osteoporosis.

Bone metabolism, in general, the mandibular trabecular bone decreases with age and also occurs in patients with the eroded cortex, as detected on panoramic radiography. Some researchers report that cortical measurements of the mandible (shape and width), as detected on panoramic radiographs, are useful screening tools for identifying individuals with low bone BMD or osteoporosis.^{8,9,10} None data describes the mechanisms underlying mandibular bone and duration HAART in HIV-infected individuals, especially in children.^{11,12}

A study explaining the relation of mandibular bone density to CD4 T-cells counts in HIV-infected children has not been conducted; based on the above description, The research objective was to analyze the correlation between the mandibular bone density with CD4 T-cells and HAART duration in HIV-infected children

METHODS

Thirty-five children 5-15 years of age in Teratai Clinic of Hasan Sadikin Hospital, Bandung, West Java, Indonesia, with HIV infected were enrolled in the study. They had high active antiretroviral therapy (HAART) for at least five years, no severe concomitants illness, and none had growth, genetic and congenital disorder. Clinical patients characterization are summarized below (see the Results). The control group included 17 children (12 girls and five boys), aged 5 to 15 years. All subjects were healthy and physically active. None had a history of chronic illness. None had taken any medication like corticosteroids or any other drug with known effect on bone metabolism, hormone, vitamin preparation, or calcium supplements regularly. All subjects underwent a blood test to calculate the value of CD4 used flow cytometry analysis.

Evaluation of Bone Mineral Density

BMD measurements were performed with a panoramic radiograph photo. BMD was measured at mandibular cortical with fractal dimension and mandibular cortical shape. Using Adobe Photoshop (Adobe Systems Inc., San Jose, CA, USA) software, the digitised radiographs were opened. The regions of interest (ROIs) of 100×100 pixels were selected from the trabecular bone

free from teeth or any superimposition. Then the image was cropped and saved in BMP format. In brief, the transferred cropped ROI was filtered using Gaussian blur; sigma=3 to remove the fine and medium scale variations in image brightness and then saved again. Using Scion image, the original ROI and the blurred one were subtracted and multiplied by one and added 128. Then the resultant image was converted to binary with the threshold at a grey level of 128.

The binary image was eroded three times and dilated three times to reduce the noise. Finally, the image was outlined and used for fractal analysis and particles. All digital manipulations and measurements were made within ROIs.¹¹ Using ImageJ, the fractal dimensions (FDs) of the outlined image were calculated by the Box Counting function.

Initially, the image was converted by a square grid of equally sized tiles; the square boxes' widths were 2, 3, 4, 6, 8, 12, 16, 32, and 64 pixels. Subsequently, the number of the counted tiles was plotted against the total number of tiles in a double logarithmic scale. Finally, FD

was calculated from the slope of the line fitted on data points.¹¹ Ethical clearance of this study was approved from the Health Research Ethics Committee of Universitas Padjadjaran, with the number of 273/UN6.CI.3.2/KEPK/PN/2015.

Statistic Analysis

The statistical analysis was carried out using SPSS Version 11 (Statistical Package for the Social Sciences, Chicago, USA). The summary data are expressed as mean values \pm SD, and comparisons between groups were done using the one-way analysis of variance test. Relationships between continuous variables were assessed by Pearson correlation and Spearman correlation. P-values were reported for all statistical tests, and values less than 0.01 were considered significant.

RESULTS

The results of this study showed that the mean CD4 cell count was $558.02 \pm 473.42 \text{ mm}^3$ and non-HIV infected was $1025.06 \pm 273.92 \text{ mm}^3$. The mean duration of HAART was 5.20 ± 1.95 years. (Table 1)

Table 1. Subject characteristic

Characteristic	N/ Mean-SD	
	HIV	Non-HIV
Sex		
Male	12	5
Female	23	12
Age	9 \pm 3 years old	10 \pm 3 years old
CD4	558.02 \pm 473.42 mm ³	1025.06 \pm 273.92 mm ³
Duration of HAART	5.20 \pm 1.95 years	-

Table 2. Fractal dimension of HIV-infected and non-HIV children

Characteristics	N (count)	Fractal dimension mean \pm SD (pixel)	P-value
HIV	35	53.73 \pm 8.05	0.0007
Non-HIV	17	61.59 \pm 7.36	

Table 3. Dimension fractal related with the CD4 level

CD4 cells count categories (mm ³)	Mean (pixel)	SD (pixel)	N (count)
HIV			
Asymptomatic (>500)	53.67	7.82	25
Mild (350-499)	58.50	-	1
Advanced (200-349)	58.50	-	1
Severe (<200)	54.48	10.53	8
Non-HIV			
Asymptomatic (>500)	61.59	7.36	17

The mean FD HIV infected children was 53.73 ± 8.05 , and non-HIV infected was 61.59 ± 7.36 . Table 3-4 showed the correlation between FD and CD4 count level in HIV infected children and non-HIV infected, respectively. The correlation between the FD in HIV infected and non-HIV infected revealed a significant correlation ($p < 0.0007$).

Based on the Mandibular cortical shape index (CI), three patients had osteoporosis, 19 osteopenia, and 13 patients had normal findings in the study group. A CI means value was calculated based on the observer's assessments. If two observers agreed on one category, this category was considered as the CI mean value.

Two observers (A, B) separately assessed the CI of all 52 panoramic radiographs. Each observer was asked to classify CI them into one of three categories according to the classification by Esin et al.¹² as follows: A. Normal cortex (C1): the endosteal margin of the cortex is even and sharp on both sides (Fig. 1A); B. Mildly to the moderately eroded cortex (C2): the endosteal margin shows semilunar defects (lacunar resorption) or appears to form endosteal cortical residues (C3) (Fig. 1B); Severely eroded cortex: the cortical layer forms heavy endosteal cortical residues and is clearly porous (Fig. 1C). The radiographs were placed on an X-Ray Film Viewer by each observer, and the CI was assessed respectively.

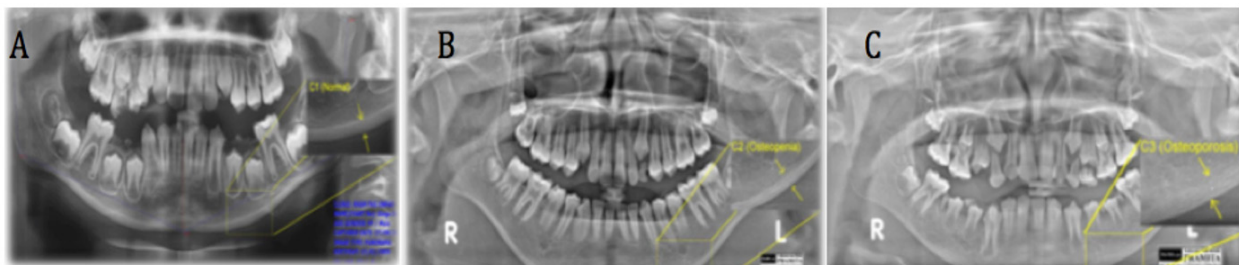


Figure 1. Categories of the mandibular cortical shape index, A: a thick version of normal cortex: the endosteal margin of the cortex is even and sharp on both sides (yellow arrows), B: mildly to moderately eroded on one side of cortex (osteopenia), C: severely eroded without the endosteal margin cortex (osteoporosis).

However, if the assessments resulted in three different categories, the middle category (osteopenia) was considered the result. None of the control group patients was assessed as having

a severely eroded cortex (osteoporosis), whereas 8.6% of HIV-infected children were judged to have sufficient cortex, some of which were severely eroded (Table 4).

Table 4. Mandibular cortical shape index of HIV-infected and non-HIV children

Characteristic	N (count)	n (count)	P-value
HIV	35	C1=14	0.006
		C2=8	
		C3=3	
Non HIV	17	C1=13	
		C2=4	

Table 5. Correlation between mandibular bone density and the CD4 T-cells

Description	Mean \pm SD	N	CD4 (mm^3)	P-value
Dimension fractal	53.73 ± 8.05	35	558.02 ± 473.42	0.06
Mandibular cortical index	1.67 ± 0.63	C1=14		0.09
		C2=18		
		C3=3		

The correlation analysis model showed a highly significant predictive value for the CI mean value ($p < 0.006$). The correlation between mandibular bone density and CD4 T-cells in the entire study population is depicted in Table 5.

All groups had comparable mean baseline values of fractal dimension and mandibular

cortical index. Fractal dimension and CD4 T-cells were significantly positive ($p = 0.06$), as shown in Table 6. The correlation between CI and CD4 T-cells demonstrated a significant positive relationship ($p = 0.09$). Mandibular bone density showed a significant positive correlation with the duration of HAART ($p = 0.0003$).

Table 6. Correlation between mandibular bone density and duration of HAART

Description	Mean \pm SD (mm ³)	N (count)	Duration of HAART (year)	P-value
Dimension fractal	53.73 \pm 8.05	35 C1 = 14	5.20 \pm 1.95	0.0003
Mandibular cortical index	1.67 \pm 0.63	C2 = 18		
		C3 = 3		

DISCUSSION

This study analysed the correlation between mandibular bone density, CD4 T-cells, and duration HAART in HIV infected children. Our data showed that mandibular density markers such as fractal dimension and mandibular cortical shape index significantly correlate with the CD4 cell count. The data suggest that decrease CD4 T-cells levels are associated with more severe osteopenia in children. BMD decreases further after antiretroviral therapy initiation. This finding highlights the fact that high bone turnover rates are associated with more rapid in children. Bone abnormalities are reported among adults and children with HIV infection.^{5,13,14}

Low BMD is common among HIV-infected subjects. HIV infection, however, may have disparate effects on BMD in pediatric compared with adult populations because of the rapid bone acquisition that occurs during childhood. The implication of HIV infection on bone growth may be of particular concern in females because 37% of bone mass is accumulated between pubertal stage 2 and pubertal stage 5 in girls.

Because females have an earlier acquisition of peak bone mass and a markedly high risk of developing osteoporosis later in life, the potential effect of HIV infection on bone acquisition may be most apparent in females in this study.^{15,16} Unlike other studies conducted by Arpadi et al.¹³, which suggested a decrease in bone mass of HIV-infected

children vertically, and osteopenia or osteoporosis in HIV-infected adults, treated with highly active antiretroviral therapy, the current research suggested that patients treated with HAART and PI-based ART had no significantly lower bone mass compared with antiretroviral or protease inhibitor-naïve patients. The immune-virological control, with concomitant clinical benefit to most patients, may suggest that osteopenia is related more to HIV infection and factors related to the natural history of the disease (i.e., maternal status, prenatal growth, prophylaxis, delayed diagnosis, etc.) than to HAART or specific classes of antiretroviral.^{13,14,15,17}

Osteopenia and osteoporosis usually analyzed by assessing BMD of the total body and lumbar spine by DEXA. This technique is known well and accurate, but expensive. In this study, we used panoramic to assess BMD with mandibular cortical index and fractal dimension. Research showed that different quantitative and qualitative indices calculated on oral panoramic radiographs had been proposed as valuable tools to screen for reduced skeletal bone mineral density.

The panoramic radiographs are considered as frequent diagnostic procedures during routine dental checkups or treatment procedure. It could be of great clinical value if dentists could use them to identify patients at a high risk of osteoporosis, including HIV-infected patient with antiretroviral therapy. In this study, the cortical index represents the ratio between the mandibular cortical width at the mental foramen region and the lower

border's distance to the mental foramen's inferior edge. The presence of cortical erosions (either C2 or C3 type) produced a sensitivity in detecting reduced BMD (T score ≤ -1). The sensitivity in the diagnosis of osteoporosis (T score ≤ -2.5). Detecting osteoporosis when the cortical layer is porous, with heavy endosteal cortical residues and eroded cortex (C3). The study results illustrate that there is a relation between immunosuppressive between HIV-infected children and non-HIV children.

Disease-related processes might act through different mechanisms. It was recently observed that bone loss occurs when a severe decrease in CD4 count is present or interleukin (IL)-6 expression is enhanced. This cytokine is known to activate osteoclast and appears to negatively interfere with IGF-1 secretion or activity. Furthermore, a decrease in calcium available for bone mineralization due to reduced intake and/or absorption, together with reduced energy and protein intake reported in HIV-infected children, may be responsible for their impaired bone acquisition.

However, results of the present study and those previously reported have to be interpreted with caution because the numbers of patients are small, and baseline bone mass measurements before starting therapy and body mass index are unknown.^{2,13,17,18} In this study, HAART-treated children with long-term therapy showed osteopenia to osteoporosis in the mandibular cortical index. It may happen because children disrupt peak bone mass and thereby increase the risk of life-long osteoporosis and fractures.^{6,19} Low levels of bone formation and increased concentrations of bone resorption indexes have been found in untreated patients.¹⁷

Moreover, one study showed that HAART could induce normalisation of bone remodelling processes in HIV-infected adults.¹⁸ More longitudinal data is required to confirm the finding of this study. Ideally, future studies should be compared with localised DEXA scan where there is greater measurement precision and the gold standard so that changes in bone density may be assessed with higher accuracy.

CONCLUSION

There is no correlation between mandibular

bone density and CD4 T-cells count and there is a correlation between mandibular bone density and duration of HAART in HIV-infected children.

ACKNOWLEDGEMENT

This project was financially supported by the PUPT Universitas Padjadjaran, West Java, Indonesia.

REFERENCES

1. Catalfamo M, Wilhelm C, Tcheung L, Proschan M, Friesen T, Park JH, et al. CD4 and CD8 T cell immune activation during chronic HIV infection: roles of homeostasis, HIV, type I IFN, and IL-7. *J Immunol.* 2011; 186(4): 2106-16. DOI: [10.4049/jimmunol.1002000](https://doi.org/10.4049/jimmunol.1002000).
2. Saccomanno MF, Ammassari A. Bone disease in HIV infection. *Clin Cases Miner Bone Metab.* 2011;8(1):33-6.
3. Ofotokun I, McIntosh E, Weitzmann MN. HIV: inflammation and bone. *Curr HIV/AIDS Rep.* 2012; 9(1): 16-25. DOI: [10.1007/s11904-011-0099-z](https://doi.org/10.1007/s11904-011-0099-z).
4. Eckard, Allison R, and Stefano Mora. "Bone health in HIV-infected children and adolescents." *Curr Opin HIV AIDS.* 2016; 11(3): 294-300. DOI: [10.1097/COH.0000000000000270](https://doi.org/10.1097/COH.0000000000000270)
5. Sudjaritruk T, Puthanakit T. Adverse bone health among children and adolescents growing up with HIV. *J Virus Erad.* 2015; 1(3): 159-67.
6. Scanlon ML, MacNaughton G, Sprague C. Neglected Population, Neglected Right: Children Living with HIV and the Right to Science. *Health Hum Rights.* 2017; 19(2): 169-181.
7. Macdonald HM, Nishiyama KK, Kang J, Hanley DA, Boyd SK. Age-related patterns of trabecular and cortical bone loss differ between sexes and skeletal sites: A population-based HR-pQCT study. *J Bone Miner Res.* 2011; 26(1): 50-62. DOI: [10.1002/jbmr.171](https://doi.org/10.1002/jbmr.171)
8. Mochizuki N, Sugino N, Ninomiya T, Yoshinari N, Udagawa N, Taguchi N. Association of cortical shape of the mandible on panoramic radiographs with mandibular trabecular bone structure in Japanese adults: a cone-beam CT-image analysis. *Oral Radiol.* 2014; 30: 160-

167. DOI: [10.1007/s11282-013-0155-z](https://doi.org/10.1007/s11282-013-0155-z)
9. Govindraj P, Chandra P. Radiomorphometric indices of the mandible - an indicator of osteoporosis. *J Clin Diagn Res.* 2014; 8(3): 195-198. DOI: [10.7860/JCDR/2014/6844.4160](https://doi.org/10.7860/JCDR/2014/6844.4160)
10. Matsuda Y, Terauchi T, Murahira K, Patil S, Joshi V, Araki K, et al. Exposure time reduction of secondary radiographs used in digital subtraction radiography in detecting intrabony change. *Oral Radiol.* 2014; 30(1): 20-6. DOI: [10.1007/s11282-013-0134-4](https://doi.org/10.1007/s11282-013-0134-4)
11. Amer ME, Heo MS, Brooks SL, Benavides E. Anatomical Variations of Trabecular Bone Structure in Intraoral Radiographs Using Fractal and Particles Count Analyses. *Imaging Sci Dent.* 2012; 42(1): 5-12. DOI: [10.5624/isd.2012.42.1.5](https://doi.org/10.5624/isd.2012.42.1.5)
12. Hastar E, Yilmaz HH, Orhan H. Evaluation of mental index, mandibular cortical index and panoramic mandibular index on dental panoramic radiographs in the elderly. *Eur J Dent.* 2011; 5(1): 60-7
13. Arpadi SM, Shiau S, Strehlau R, Patel F, Mbeti N, McMahon DJ, et al. Efavirenz is associated with higher bone mass in South African children with HIV AIDS. 2016 23;30(16): 2459-2467. DOI: [10.1097/QAD.0000000000001204](https://doi.org/10.1097/QAD.0000000000001204).
14. Dimeglio I, Wang J SG. Bone Mineral Density in Children and Adolescents with Perinatal HIV Infection. *AIDS.* 2013; 27(2): 211-20. DOI: [10.1097/QAD.0b013e32835a9b80](https://doi.org/10.1097/QAD.0b013e32835a9b80)
15. Chang CJ, Chan YL, Pramukti I, Ko NY, Tai TW. People with HIV infection had lower bone mineral density and increased fracture risk: A meta-analysis. *Arch Osteoporos.* 2021; 16(1): 47. DOI: [10.1007/s11657-021-00903-y](https://doi.org/10.1007/s11657-021-00903-y)
16. Bunders MJ, Frinking O, Scherpbier HJ, van Arnhem LA, van Eck-Smit BL, Kuijpers TW, Zwinderman AH, et al. Bone mineral density increases in HIV-infected children treated with long-term combination antiretroviral therapy. *Clin Infect Dis.* 2013; 56(4): 583-6. DOI: [10.1093/cid/cis917](https://doi.org/10.1093/cid/cis917).
17. Cohen MS, Muessig KE, Smith MK, Powers KA, Kashuba ADM. Antiviral agents and HIV prevention: Controversies, conflicts, and consensus. *AIDS.* 2013; 26(13): 1585-98. DOI: [10.1097/QAD.0b013e3283543e83](https://doi.org/10.1097/QAD.0b013e3283543e83)
18. Sindeaux R, Figueiredo PTDS, De Melo NS, Guimarães ATB, Lazarte L, Pereira FB, et al. Fractal Dimension and Mandibular Cortical Width in Normal and Osteoporotic Men and Women. *Maturitas.* 2014; 77(2): 142-8. DOI: [10.1016/j.maturitas.2013.10.011](https://doi.org/10.1016/j.maturitas.2013.10.011).
19. Grant PM, Kitch D, McComsey GA, Dube MP, Haubrich R, Huang J. et al. Low baseline CD4+ count is associated with greater bone mineral density loss after antiretroviral therapy initiation. *Clin Infect Dis.* 2013; 57(10): 1483-8. DOI: [10.1093/cid/cit538](https://doi.org/10.1093/cid/cit538).