

β-carotene gingival mucoadhesive patch on Cx-43 and 8-Oxo-dg expression to prevent micronucleus formation due to panoramic radiography exposure

Rurie Ratna Shantiningsih^{1*}, Suwaldi², Indwiani Astuti³, Munakhir Mudjosemedi¹

¹Department of Dentomaxillofacial Radiology, Faculty of Dentistry Gadjah Mada University, Indonesia

²Department of Pharmaceutics, Faculty of Pharmacy Gadjah Mada University, Indonesia

³Department of Pharmacology and Therapy, Faculty of Medicine, Public Health, and Nursing Gadjah Mada University, Indonesia

ABSTRACT

Introduction: β-carotene as a lipid-soluble antioxidant substance, expected to prevent the oxidative reaction and to improve the junctional communication detected by Cx-43. Micronucleus is known as one of the early markers of DNA damage which might be related to carcinogenesis mechanism that increased by panoramic radiography radiation exposure. The objective of this research was to analyse the effect of the β-carotene gingival mucoadhesive patch on Cx-43 expression and 8-oxo-dG to prevent micronucleus formation at the gingival mucosa of New Zealand rabbit due to panoramic radiography radiation exposure. **Methods:** β-carotene gingival mucoadhesive patch was applied to gingival mucosa of the experimental rabbits. In Group I, the rabbits without patch was a control group. Group II has applied the patch before radiography exposures, Group III during the radiography exposures, and Group IV after radiography exposures. Micronucleus samples were taken from the rabbit's swabbed gingival mucosa, then stained using modified Feulgen-Rossenbeck. The 8-oxo-dG and Cx-43 expressions were detected using immunohistochemistry technique. The results were then analysed using two-way ANOVA. **Results:** The increasing number of micronucleus in Group I had a different mean ($p < 0.05$) with Group III and IV. The expression of 8-oxo-dG and Cx-43 had significant differences ($p < 0.05$) between Group I and III. This result indicated that β-carotene gingival mucoadhesive patch prevents the increasing number of micronucleus especially when it applied before and during panoramic radiography radiation exposure by the increasing Cx-43 and decreasing 8-oxo-dG expression. **Conclusion:** The β-carotene gingival mucoadhesive patch can be utilised to prevent the panoramic radiography radiation exposure's effect.

Keywords: β-carotene, gingival-mucoadhesive patch, micronucleus, radiation exposure

P-ISSN 1979-0201, e-ISSN 2549-6212; Available from: <http://jurnal.unpad.ac.id/pjd/article/view/16351>

DOI: [10.24198/pjd.vol31no1.16351](https://doi.org/10.24198/pjd.vol31no1.16351)

Submission: Apr 12, 2018; Accepted: Feb 14, 2019; Published online: Mar 29, 2019

*Corresponding author: Rurie Ratna Shantiningsih, Department of Dentomaxillofacial Radiology, Faculty of Dentistry Gadjah Mada University, Indonesia. Denta 1, Sekip Utara, Yogyakarta, Special Region of Yogyakarta, Indonesia, 55281. Phone: +6281328712276; Email: rurieratna@ugm.ac.id

INTRODUCTION

Panoramic radiography is very common to use in dentistry due to its low dose category which is 47 μ Sv.¹ The very low dose of panoramic radiography exposure had many effects on all tissues and living cells exposed.² Many previous research^{3,4,5} found that the radiation of X-rays from dental radiographs using panoramic technique cause genotoxic effects by increasing the number of micronucleus in epithelial cells of the gingiva and buccal mucosa. Micronucleus is one of the earliest signs of DNA damage and related to the mechanism of carcinogenesis and often believed to be a marker in the affected cells by the genotoxic effect.^{6,7} The genotoxic effects resulted in deoxyribonucleic acid (DNA) damage and the formation of DNA adduct.^{8,9} DNA adduct can be identified by the expression of 8-hydroxy-2-deoxyguanosine (8-oxo-dG) caused by oxidative reactions due to X-rays exposure.¹⁰

Beta-carotene is one of the antioxidant agents which has been known as an anticancer. The β -carotene mechanism in preventing carcinogenesis is considered by its double bond to scavenge free radicals and its ability as a facilitator of communication between gap junctions.¹¹ The gap junctions composed by transmembrane proteins called connexin, one of them is Connexin-43 (Cx-43) which facilitate communication between gap junctions.¹² In mucoadhesive patch formula, drug absorption can be directly localised to the area where the patch is placed.¹³ Rabbit as experimental animals has a character as the turn-over period from gingival mucosa which is similar to human's, ranged between 10-12 days.¹⁴ Therefore, local administration of β -carotene in the rabbit's oral cavity will be given in the form of gingival mucoadhesive patches in the experimental animal. The objective of this research was to analyse the effect of the β -carotene gingival mucoadhesive patch on Cx-43 expression and 8-oxo-dG to prevent micronucleus formation at the gingival mucosa of New Zealand rabbit due to panoramic radiography radiation exposure.

METHODS

This research was obtained an Ethical Clearance from the Ethical Committee of Faculty of Dentistry

Gadjah Mada University (No.287/KKEP/FKG-UGM/EC/2012). This research was an experimental study using male rabbits of New Zealand groove. The samples were divided into four groups. Group I was the control group that was exposed to panoramic radiography without β -carotene gingival mucoadhesive patch application. Group II was applied with the β -carotene gingival mucoadhesive patch for 3, 6, and 9 days consecutively, before panoramic radiography exposure. Group III was received the β -carotene gingival mucoadhesive patch application a moment before panoramic radiography exposure, and kept using the patch until 3, 6, and 9 days after exposure respectively. Group IV was applied with the β -carotene gingival mucoadhesive patch after 3, 6, and 9 days of panoramic radiography exposure.

The period of 3, 6, and 9 days were chosen related the prior research which showed that the micronucleus increasing on rabbit's gingival mucosa reached the peak on 9 days after exposure.¹⁵ Three rabbits represented each application group. The β -carotene gingival mucoadhesive was applied at the labial gingival mucosa of the rabbits (Figure 1).

The panoramic radiography exposure was performed using Yoshida® Panoura panoramic radiography machine with the specification of 80 kVp, 8 mA, 12 seconds, with a dose of 47 μ Sv

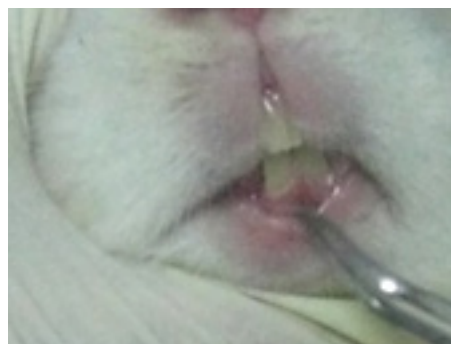


Figure 1. The β -carotene gingival mucoadhesive patch application at the rabbit's labial gingival mucosa

for one-time exposure with the dose rate of 47 μ Sv.¹ Measurement of the number of micronucleus before and after panoramic radiography exposure was done by swabbing in the anterior gingival mucosa using a cervical brush.

The swabbed sample was stained with Feulgen-Rossenbeck modification method. Micronucleus identification was considered to be

the distinctively individualised structures with the criteria as follows: 1) round/oval shape with smooth border; 2) size range from one-fifth and one-third of the main nucleus's size; 3) located near but separated with the main nucleus; 4) Feulgen positive; 5) presenting similar staining with the main nucleus that showed chromatin distribution; 6) not overlap with the other cell.^{3,5} For each slice, a minimum of 1000 cells was studied by blind analysis. Micronucleus was detected under a light microscope connecting OptiLab Viewer® (x400).

Immunohistochemistry (IHC) examination was conducted to examine the changes in the 8-oxo-dG and Cx-43 expression to observe the

effect of β -carotene gingival mucoadhesive patch application. The IHC examination was carried out on samples of labial gingival mucosa of rabbits which had been decapitated before. Anti-8-oxo-dG Mab Clone 2E2 antibody (Trevigen®) and Anti-connexin 43 GJA1 mouse monoclonal antibody (Abcam®) were used as the primary antibody and Trekki® Universal-Link for the secondary antibody. A quantitative calculation of the positive cell number in IHC examination was performed with 10x magnification for 8-oxo-dG and 40x for Cx-43. Furthermore, after all of the data showed the normal distribution by Shapiro-Wilk normality test ($p > 0.05$). The calculation of micronucleus number, 8-oxo-dG, and Cx-43 score was statistically analysed using two-way ANOVA.

RESULTS

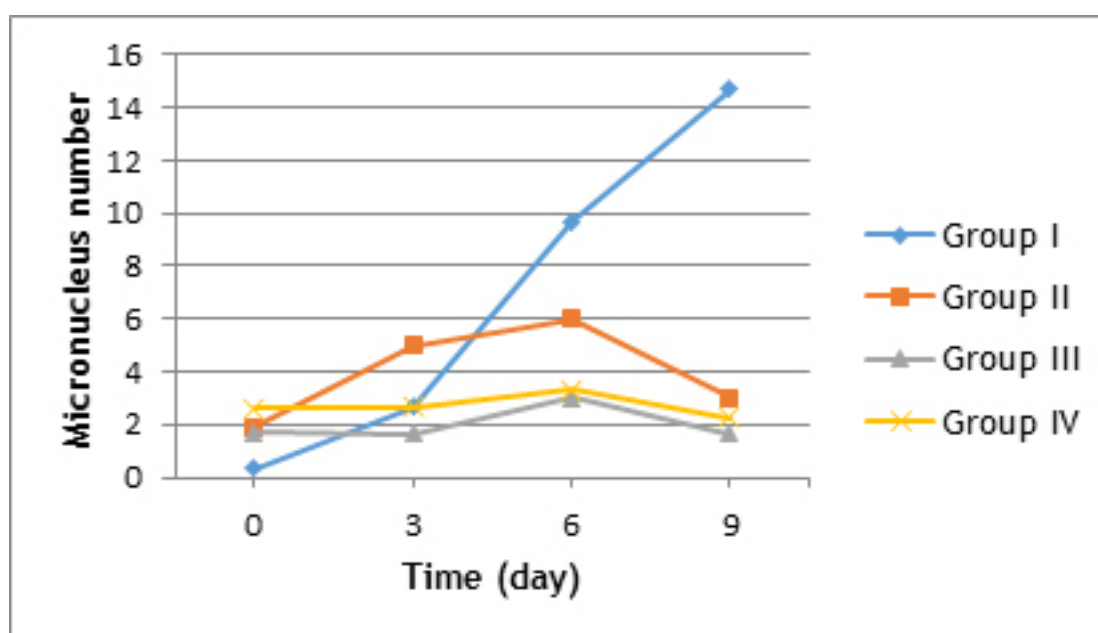


Figure 2. The micronucleus number of each groups related days

Figure 2 shows the highest micronucleus number increase was found on Group I on the 3rd day after radiography exposure. There was also a slight increase in micronucleus number of another group in the 3rd day after exposure and decreasing after 6 days. Group IV showed relatively stagnant micronucleus increase.

Based on Figure 3, the highest increase of Connexin 43 expression was found in Group IV. Group I showed no increasing of Cx-43 expression because they did not apply with the β -carotene gingival mucoadhesive patch. Group III showed a

decrease of Cx-43 expression after 6 days. Group II showed an increase of Cx-43 expression after the 3rd day because the application started 3 days after exposure.

Figure 4 shows that the 8-oxo-dG expression was decreased in all groups except Group IV that relatively stable. Group I showed the highest expression and slightly decreasing after 6 days. The 8-oxo-dG expression from other group indicated lower expression than Group I. The statistical analysis was performed using the two-way ANOVA and presented in the following Tables.

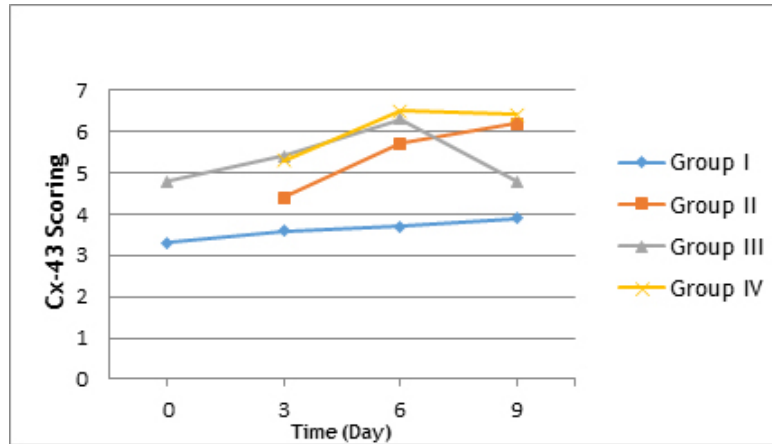


Figure 3. The Cx-43 expression of each group

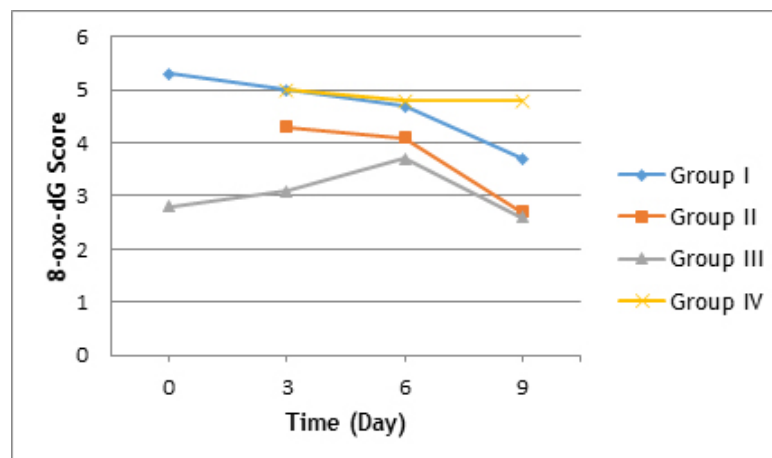


Figure 4. The 8-oxo-dG expression of each group

Table 1. Two-way ANOVA result of micronucleus expression

Category	Db	Mean square	Sig(2-tailed)
Each day	3	73.000	0.000*
Each group	3	85.407	0.000*
Each day and group	6	31.074	0.004*

Table 2. Two-way ANOVA result of Cx-43 expression

Category	Db	Mean square	Sig(2-tailed)
Each day	3	2.590	0.002*
Each group	3	6.205	0.000*
Each day and group	6	1.368	0.011*

Table 3. Two-way ANOVA result of 8-oxo-dG expression

Category	Db	Mean square	Sig(2-tailed)
Each day	3	1.679	0.045*
Each group	3	8.394	0.000*
Each day and group	6	1.101	0.090

There were significantly different ($p < 0.05$) about the result of micronucleus expression and Cx-43 expression in each group, each day and also related day and group (Table 1 and 2). In the other hand, Table 3. showed 8-oxo-dG expression of each day and group category was not differently significant ($p > 0.05$).

DISCUSSION

This research showed a significant effect ($p < 0.05$) by two-way-ANOVA analysis of β -carotene gingival mucoadhesive patch application to prevent the increasing number of micronucleus. The number of micronucleus in group II, III, and IV were lower than group I (Table 1). Figure 2 showed a reduction of the micronucleus number in Group II, III, and IV after application of β -carotene gingival mucoadhesive patch, especially at the 6th and 9th day compared to Group I as control.

This results showed that the β -carotene gingival mucoadhesive patch could serve as a prohibition of micronucleus increase due to panoramic radiography exposure, especially when given as prevention. It was further reassured by the results of the significant correlation between the amount of β -carotene that penetrated the gingiva with the presence of micronucleus in Group II and III. In Group IV, application of a β -carotene gingival mucoadhesive patch will stop the oxidation reaction due to panoramic radiography exposure by breaking the chain reaction of oxidation and functioned as an oxidation reaction chain-breaker.¹³

The effect of the β -carotene gingival mucoadhesive patch applied to the expression of 8-oxo-dG showed a significant expression difference between Group I with Group II and III ($p < 0.05$) by two-way ANOVA statistical analysis (Table 3). Furthermore, from the result of IHC showed in Group III, which were applied β -carotene gingival mucoadhesive patch a moment before panoramic radiography exposure obtained a very low expression of 8-oxo-dG (Figure 4).

This result indicated that the application of β -carotene gingival mucoadhesive patch also gives a physical effect toward side effects of panoramic radiography exposure. Thereby can be expected that the use of β -carotene mucoadhesive gingival patch can help to protect the gingiva from x-rays

exposure and restrain oxidation reaction that occurred in saliva to gingiva so that the oxidation reaction can be minimised.^{9,10} This study indicated that the function of the β -carotene gingival mucoadhesive patch not only as an antioxidant to quench singlet oxygen but also as oxidation reaction chain-breaker.¹³ Also, as physical protection when it was applied at the time of panoramic radiography exposure. The effect of the β -carotene gingival mucoadhesive patch applied to the expression of Cx-43 showed a significant difference ($p < 0.05$) between Group I and Group II, III, and IV by two-way ANOVA statistical analysis (Table 2). The results of the correlation between the amount of β -carotene that were applied into the gingival mucosa along with the increasing of Cx-43 expressions, appeared to be significant in Group II and III. These results indicated that the β -carotene gingival mucoadhesive patch application was associated with the increasing of Cx-43 expression (Figure 3), especially if administered before exposure or at the moment of exposure. Zhang¹² have explained that carotenoids, including β -carotene, can enhance the gap junction communication, which was characterised by increased expression of the gene connexin-43 (Cx-43). Although the β -carotene that were used in this study only in low concentration, it was able to provide a protective effect to prevent the increasing number of micronucleus after panoramic radiography exposure. This result was correlated with β -carotene ability as an endogenous antioxidant in the body tissues.¹⁶

These results indicated that the β -carotene gingival mucoadhesive patch application a moment before panoramic radiography exposure may be able to act as a preventive agent for the DNA adduct formation and increasing number of micronucleus. This effect was occurred the communication mechanism in gap junction which expressed by Cx-43. The function as a protective agent was more effective to be used at the time of exposure than if administered before and after panoramic radiography exposure.

CONCLUSION

The β -carotene gingival mucoadhesive patch can be utilised to prevent the panoramic radiography radiation exposure's effect.

ACKNOWLEDGEMENT

This research was supported by research grants from the Faculty of Dentistry of Gadjah Mada University.

REFERENCES

1. Kurniawati L. Kalibrasi Spasial Citra Radiografi dan Kalibrasi Dosis Mesin Sinar X Panoramik Gigi [thesis]. Yogyakarta: Gadjah Mada University; 2013. p. 59-60.
2. Whaites E, Drage N. Essential of Dental Radiography and Radiology. 5th ed. London: Churchill Livingstone; 2013. p. 57-64.
3. Cerqueira EM, Meireles JR, Lopes MA, Junqueira VC, Gomes-Filho IS, Trindade S, et al. Genotoxic effects of X-rays on keratinized mucosa cells during panoramic dental radiography. *Dentomaxillofac Radiol*. 2008; 37(7): 398-403. DOI: [10.1259/dmfr/56848097](https://doi.org/10.1259/dmfr/56848097)
4. Ribeiro DA. Cytogenetic biomonitoring in oral mucosa cells following dental X-ray. *Dentomaxillofac Radiol*. 2012; 41(3): 181-4. DOI: [10.1259/dmfr/14555883](https://doi.org/10.1259/dmfr/14555883)
5. Yang P, Hao S, Gong X, Li, G. Cytogenetic Biomonitoring in Individuals Exposed to Cone Beam CT: Comparison among Exfoliated Buccal Mucosa Cells, Cells of Tounge and Epithelial Gingival Cells. *Dentomaxillofac Radiol*. 2017; 46(5): 20160413. DOI: [10.1259/dmfr.20160413](https://doi.org/10.1259/dmfr.20160413)
6. Loft S, Høgh Danielsen P, Mikkelsen L, Risom L, Forchhammer L, Møller P. Biomarkers of Oxidative Damage to DNA and Repair. *Biochem Soc Trans*. 2008; 36(Pt 5): 1071-6. DOI: [10.1042/BST0361071](https://doi.org/10.1042/BST0361071)
7. Borthakur G, Butryee C, Stacewicz-Sapuntzakis M, Bowen PE. Exfoliated Buccal Mucosa Cells as a Source of DNA to Study Oxidative Stress. *Cancer Epidemiol Biomarkers Prev*. 2008; 17(1): 212-9. DOI: [10.1158/1055-9965.EPI-07-0706](https://doi.org/10.1158/1055-9965.EPI-07-0706)
8. Whaites E, Drage N. Radiography and Radiology for Dental Care Professionals. 2nd ed. London: Churchill Livingstone; 2009. p. 29-32.
9. Tremblay L. Genetic Effects of Radiation Exposure [homepage on internet]. 2010. [cited 2018 Mar]; [about 2 screens]. Available from: <http://www.livestrong.com/article/180149-genetic-effect-of-radiation>.
10. Wulff BC, Schick JS, Thomas-Ahner JM, Kusewitt DF, Yarosh DB, Oberyshyn TM. Topical Treatment with OGG1 Enzyme Affects UVB-induced Skin Carcinogenesis. *Photochem Photobiol*. 2008; 84(2): 317-21. DOI: [10.1111/j.1751-1097.2007.00257.x](https://doi.org/10.1111/j.1751-1097.2007.00257.x)
11. Fiedor J, Burda K. Carotenoids as Antioxidant in Human Health and Disease. *Nutrients*. 2014; 6(2): 466-88. DOI: [10.3390/nu6020466](https://doi.org/10.3390/nu6020466)
12. Mueller L, Boehm V. Antioxidant Activity of B-carotene Compound in Different in Vitro Assays. *Molecules*. 2011; 16(2): 1055-69. DOI: [10.3390/molecules16021055](https://doi.org/10.3390/molecules16021055)
13. Shah D, Gaud RS, Misra AN, Parikh R. Formulation of A Water Soluble Mucoadhesive Film of Lycopene For Treatment of Leukoplakia. *Int J Pharm Sci Rev Res*. 2010; 2(1): 6-10.
14. Misra A. Challenges in Delivery of Therapeutic Genomics and Proteomics. Amsterdam: Elsevier; 2010. p. 482-3.
15. Shantiningsih RR, Suwaldi, Astuti I, Mudjosemedi M. Peningkatan Jumlah Mikronukleus pada Mukosa Gingiva Kelinci setelah Paparan Radiografi Panoramik. *Maj Ked Gi Ind*. 2013; 20(2): 119-25. DOI: [10.22146/majkedgiind.6738](https://doi.org/10.22146/majkedgiind.6738)
16. Mueller L, Boehm V. Antioxidant Activity of B-carotene Compound in Different in Vitro Assays. *Molecules*. 2011; 16(2): 1055-69. DOI: [10.3390/molecules16021055](https://doi.org/10.3390/molecules16021055)