

# Efficacy of platelet-rich fibrin application for improving collagen density of gingival connective tissue in periodontitis-induced rabbits

Aini Hariyani Nasution<sup>1</sup>, Wenny Dewanti<sup>1</sup>

<sup>1</sup>Department of Periodontology, Faculty of Dentistry Universitas Sumatera Utara, Indonesia

## ABSTRACT

**Introduction:** Due to the high prevalence of periodontal diseases that increase the possibility of tooth loss, platelet-rich fibrin (PRF) as a regenerative treatment has been proposed. PRF is a potential second-generation platelet concentrate and autologous healing biomaterial which contain growth factors that accelerate wound healing mechanisms. This study aimed to evaluate the efficacy of platelet-rich fibrin application to improve gingival connective tissue collagen density in periodontitis-induced rabbits.

**Methods:** An experimental study with a post-test only control group design approach was conducted on 20 samples calculated using the Federer formula. Periodontitis was induced in ten rabbits with silk ligatures tied around the cervical region of central incisors teeth bilaterally for 14 days. After periodontitis occurred, phase I treatment was performed and followed by curettage. Using a split-mouth design, PRF was placed in the lower region as a treatment group whereas a control group without PRF was in the upper jaw region. Subjects were euthanised after the 7th and 14th days of healing. Histopathological analysis was performed, and collagen density was quantified using ImageJ software. Statistical analysis was carried out using paired-T and two-way ANOVA tests. **Results:** There was a significant difference ( $p=0.001$ ;  $p<0.05$ ) in gingival connective tissue collagen density between treatment and control groups on the 7th and 14th days of observation. There was a significant increase in gingival connective tissue collagen density in the treatment group. **Conclusion:** Platelet-rich fibrin could improve collagen density of gingival connective tissue in periodontitis-induced rabbits.

**Keywords:** platelet rich fibrin; collagen; periodontitis

p-ISSN: 1979-0201; e-ISSN: 2549-6212; Available from: <http://jurnal.unpad.ac.id/pjd/article/view/31891>

DOI: [10.24198/pjd.vol34no1.31891](https://doi.org/10.24198/pjd.vol34no1.31891)

Submission: Jan 24, 2021; Accepted: Mar 31, 2022; Published online: Mar 31, 2022

## INTRODUCTION

Periodontal disease is a local inflammation initiated by dental plaque bacteria.<sup>1,2</sup> The prevalence of periodontal disease in its severe forms affects 11% of the global population.<sup>3</sup> Periodontitis is a chronic

inflammatory disease resulting in irreversible damage within the supporting teeth leading to connective tissue and alveolar bone attachment loss. This loss often causes a periodontal pocket formation. Periodontitis always begins with inflammation of the gingiva, known as gingivitis.<sup>1,2</sup>

---

\*Corresponding author: Wenny Dewanti, Department of Periodontology, Faculty of Dentistry Universitas Sumatera Utara, Indonesia Phone: +62 852-1549-0853 e-mail: [wennykwokk96@gmail.com](mailto:wennykwokk96@gmail.com)

Gingival curettage is a surgical procedure that is indicated if the inflammation of the gingiva persists after scaling and root planing.<sup>2</sup> This surgical technique removes the inflamed soft tissue lateral to the pocket wall and the junctional epithelium by using a curette. It was designed to promote a new connective tissue attachment to the tooth.<sup>2,4</sup>

Regenerative periodontal therapy is designed to stop the bacteria inflammation and restore the structure and function of the periodontium, thereby promoting the formation of alveolar bone, cementum and the new attachment of connective tissue and periodontal ligament.<sup>2,3,6,7</sup> One of the essential factors accelerating and enhancing the wound healing mechanisms is platelet-derived products, had been widely used in regenerative therapy. Growth factors released from activated platelets play a crucial role in wound healing and promoting tissue regeneration.<sup>6,7,8</sup>

Platelet-rich fibrin (PRF) is a potential second-generation platelet concentrate and autologous healing biomaterial. The preparation of PRF is simple because it does not require any additional anticoagulants.<sup>7</sup> Pradeep et al.<sup>9</sup> researched the treatment of intrabony defects in chronic periodontitis with PRF combined with porous hydroxyapatite (HA) graft. The results showed that PRF reduces pocket depths and promotes clinical attachment significantly in the treatment group.<sup>9</sup> Tunali et al.<sup>10</sup> concluded that using PRF centrifuged in titanium tubes could induce the formation of new bone with new connective tissue in a rabbit model of mucoperiosteal flaps within 30 days of treatment.

Eren et al. investigated the effect of PRF on angiogenesis markers vascular endothelial growth factor (VEGF), CD31, and CD34 in gingival tissue samples. At one month, the collagen fibers density in the middle submucosal site in the PRF group was higher than in the connective tissue graft group. In histological evaluation, coronally advanced flap with PRF results in earlier vessel formation and tissue maturation than connective tissue graft without PRF.<sup>11</sup>

PRF accelerates wound healing mechanisms via affecting angiogenesis, immunity, and epithelial proliferation. In addition, the PRF membrane releases many growth factors such as TGF $\beta$ 1, PDGF-AB, VEGF, and thrombospondin-1 (TSP-1). These components play important roles in

wound-healing processes whereas they have been shown to induce substrate adhesion or migration for neutrophils, macrophages, fibroblasts, and endothelial cells. Macrophages trapped inside the fibrin texture release some cytokines such as TGF, IL-1, and TNF- $\alpha$  are responsible for stimulating keratinocytes and collagen production. These cytokines have an important role against the pro-inflammatory mediators in the inflammatory process of wound healing.<sup>7,8,12</sup>

Numerous studies have been conducted on PRF as a potential periodontal regenerative therapy, especially in soft tissue healing.<sup>7,8,9,10</sup> However, there were only a few studies of PRF mechanisms in stimulating wound healing, especially in stimulating internal stem cells sources related to periodontal regeneration in periodontitis. This study aimed to evaluate the efficacy of platelet-rich fibrin application to improve gingival connective tissue collagen density in periodontitis-induced rabbits.

## METHODS

An experimental study with a post-test only control group design approach was conducted on 20 samples calculated using the Federer formula. A total of ten New Zealand local male rabbits (*Oryctolagus cuniculus*) aged 6-8 months old, weighed between 2 and 2.8 kg, were selected for this study. A split-mouth design was performed; therefore, PRF was placed in the lower region as a treatment group, whereas the control group without PRF was in the upper region of the jaws. Unfortunately, one rabbit died due to operator failure on the seventh day of wound healing observation, resulting in the total samples used in this research being reduced to 18 samples. All experimental procedures and protocols used in this investigation were reviewed and approved by the Animal Ethics Committee of the Faculty of Veterinary Medicine IPB University, Indonesia, with the approval number of 110/KEH/SKE/VIII/2018.

Ligature placement was performed under general anaesthesia. Weight was recorded, and rabbits were anesthetised using 25 mg/kg ketamine and 3 mg/kg xylazine intramuscularly. Probing was done to determine the gingival sulcus depth in the normal state. Prior to easing the installation of ligation, the interdental gingiva

was incised slightly by using a number 11 scalpel blade. Then, another incision was performed on the gingival sulcus, causing periodontal loss of attachment. Next, ligatures (4-0 braided silk sutures) were tied around the cervical region of central incisors teeth bilaterally on the maxilla and mandible. After that, glass ionomer cement was applied to the ligatures to prevent sutures from falling out. Ligatures were checked daily, and lost sutures were replaced immediately. Ligatures were removed after two weeks, and probing was performed to determine periodontal pocket formation.

Animals were monitored by daily health checks, including food and fluid intake, urination, weight gain or loss and general behaviour. Periodontitis calibration followed the clinical assessments, such as gingival inflammation, periodontal pocket formation and periodontal attachment loss.

Blood samples were collected from nine rabbits. A total of 2 ml of blood from each rabbit was drawn with a syringe from the marginal ear vein in one attempt and transferred to a plain tube without using an anticoagulant. Tubes were immediately centrifuged at 3500 rpm for 15 min 10 using Gemmy PLC-05 centrifugation at room temperature. After centrifugation, the fibrin clots in the middle part of the tube were separated using sterile tweezers and placed on sterile Nierbekken. Fibrin membranes were obtained by pressing fibrin clots with flat laboratorium glasses.

Prior to the surgery, supra and subgingival SRP procedure were performed under local anaesthesia, followed by curettage with Gracey #1-2 and #3-4 curettes. PRF was inserted after curettage in the lower region of the jaws as a treatment group. The periodontal dressing was placed after curettage in both regions and removed after one week. Four rabbits were

euthanised on the seventh day of wound healing. The mandible and maxilla of rabbits were dissected free of muscles and soft tissue, keeping the attached gingiva intact with the alveolar bone and fixated in 10% buffered formalin. Five rabbits were euthanised on the fourteenth day of healing, and the same procedures as the seventh day of healing were repeated.

The specimens were immersed in a decalcification solution and were replaced every 24 hours for two days. The specimens were cut into smaller pieces, and dehydration was performed in ascending concentrations of alcohol (70%, 80%, 95%, 100%) for 2 hours. The specimens were soaked in xylol twice, embedded in paraffin and cut into buccal and lingual cross-sections. According to the standard methods, the sections were stained with masson's trichrome stain. Collagen fibers were stained in blue colour and examined under Olympus light microscopy. ImageJ software was used to quantify the percentage of blue staining for collagen density in the whole area of each image. The collagen density will appear as red colour in the software times repetition. The research data results were processed by ANOVA and Post Hoc test on a Statistical Product and Service Solution (SPSS) software.

## RESULTS

Collagen density of gingival connective tissue mean value assessment was presented in Figure 1. Collagen mean value in the treatment group was higher than the control group on the seventh and fourteenth days of healing. The mean value of collagen density was higher in the treatment group with PRF than in the control group. The collagen fibers in Figure 2 and Figure 3 showed that the fibers in the treatment group were thicker and denser than the control group.

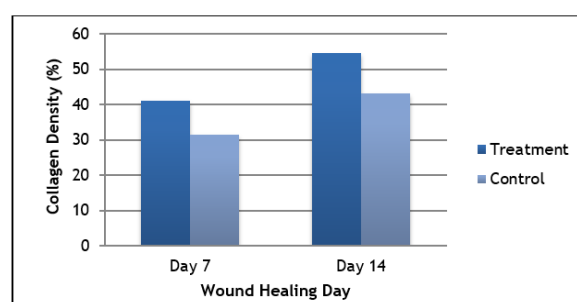


Figure 1. Diagram of average percentage (%) of collagen density on the seventh and fourteenth days of healing




Figure 2. Collagen density histopathological features on the seventh day of healing at 40x magnification; A. Treatment group; B. Treatment group on ImageJ software; C. Control group; D. Control group on ImageJ software

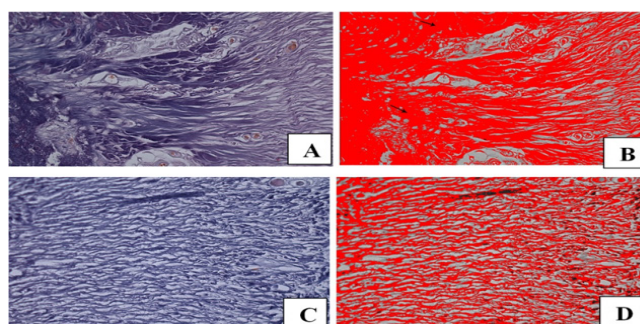


Figure 3. Collagen density histopathological features on the fourteenth day of healing at 40x magnification; A. Treatment group; B. Treatment group on ImageJ software; C. Control group; D. Control group on ImageJ software

Paired t-test was used to analyse the collagen density between treatment and control groups, presented in Table 1. A statistically significant difference was shown ( $p=0.001$ ;  $p<0.05$ ) in the gingival connective tissue of collagen density in the treatment group compared to the control group. Shapiro-Wilk normality test and Levene's

homogeneity tests were used to assess the data's normality and homogeneity before proceeding to the two-way ANOVA test. The results showed that the data used in this study were normally distributed and homogenous. Hence, two-way ANOVA assessed the collagen density between both groups based on the healing periods.

Table 1. Comparison of collagen density between groups analyzed by using paired t-test

| Groups    | n | Mean Ranks | p-value |
|-----------|---|------------|---------|
| Treatment | 9 | 48.36      | 0.001*  |
| Control   | 9 | 38.33      |         |

\*  $p < 0.05$ , significant

Based on the data presented in Table 2 shows a statistically significant difference in collagen density ( $p=0.002$ ;  $p<0.05$ ) in the treatment group compared to the control group on the seventh day of healing. In addition, a statistically significant difference ( $p=0.001$ ;

$p<0.05$ ) was also found between the treatment and control group on the fourteenth day of healing. Therefore, significant differences in gingival connective tissue collagen density between the treatment and control groups were found on the seventh and fourteenth days of healing.

Table 2. Comparison of collagen density between treatment and control groups based on healing periods analysed with two-way ANOVA

| Healing Periods      | Groups    | n | Mean Ranks | p-value |
|----------------------|-----------|---|------------|---------|
| 7 <sup>th</sup> day  | Treatment | 4 | 41.00      | 0.002*  |
|                      | Control   | 4 | 31.51      |         |
| 14 <sup>th</sup> day | Treatment | 5 | 54.65      | 0.001*  |
|                      | Control   | 5 | 43.18      |         |

\*  $p < 0.05$ , significant

## DISCUSSION

Platelet-rich fibrin developed in France by Choukroun et al.<sup>7</sup> is a strictly autologous fibrin matrix containing many platelets and leukocytes. The fibrin clot has a very dense fibrin network in which platelets and leukocytes are entrapped and activated in natural mechanisms, thus releasing growth factors and cytokines at a slow rate for seven days or more.<sup>7</sup> Therefore, PRF is widely used in periodontal regeneration due to its ability in enhancing both soft and hard tissue healing.<sup>7,8,9</sup>

The present study findings suggested that the potential function of PRF in wound healing was investigated in the collagen density of gingival connective tissue in a rabbit model of periodontitis. The present study provides evidence for the uses of PRF application post curettage in periodontitis treatments. The results showed that PRF application post curettage promoted the collagen density of gingival connective tissue in the rabbit periodontitis model, which indicated that the usage of PRF has shortened the tissues' healing periods that were damaged before as the result of periodontitis.

Figure 1 showed that the average collagen density in the treatment group with PRF was higher than the control group during each healing period. The collagen density histopathological features in Figures 2 and 3 show thicker red colour on the fourteenth day of healing. These results mean the collagen density was higher on the fourteenth day of healing in treatment and control groups. The statistical tests in Table 1 and Table 2 showed a significant difference ( $p < 0,05$ ) in gingival connective tissue collagen density between treatment and control groups during each healing period.

Natural growth factors can explain PRF results, such as platelet-derived growth factors (PDGF) and transforming growth factor-beta (TGF- $\beta$ ).<sup>7,8</sup> Choukroun et al.<sup>7</sup> stated that PRF slowly releases significant growth factors for at least seven days. These growth factors play a crucial role in connective tissue repair by promoting collagen of gingival connective tissue. PDGF stimulates fibroblasts proliferation which accelerates extracellular matrix and collagen formation, resulting in accelerating the process of wound healing. TGF- $\beta$  is responsible for the

migration of fibroblasts to the wound site and synthesises collagen directly. Combining these two major growth factors in collagen synthesis promotes gingival connective tissue collagen density.<sup>7,8</sup>

The statistical test in Table 2 also showed that the treatment group had a significant difference ( $p < 0,05$ ) in collagen density compared to the control group on the seventh and fourteenth days of healing. The treatment group had a higher collagen density than the control group during both healing periods. These results were in line with a study conducted by Kiani et al.<sup>13</sup>, in which collagen was found to be visible in the wound site on the third day to 2 weeks after injury. On the seventh day after the injury, more natural collagen fibers and fibroblast cells promotion were found. On the fourteenth day after the injury, collagen fibers will reach their stability and become a more organised arrangement on the wound site.<sup>13</sup>

Sari et al.<sup>14</sup> investigated the differences in the wound healing process during the proliferation phase after applying PRF and amniotic membranes. The results showed that fibroblasts, angiogenesis, collagen density, and epithelial thickness were higher in the PRF membranes group than in the amniotic membranes or the control group. Their study concluded that histological parameters measured during the proliferation phase showed that the PRF membrane might accelerate wound healing better than the amniotic membrane.<sup>14</sup>

A study conducted by Pradeep et al.<sup>9</sup> had similar results to the current findings, which showed a significant reduction in pocket depth and increased clinical attachment level with the use of PRF in the study group compared to the control group.<sup>9</sup> Thorat et al.<sup>14</sup> investigated the clinical and radiological effectiveness of autologous PRF in the treatment of intrabony defects in chronic periodontitis patients and reported a higher reduction in pocket depth, more gain in clinical attachment level and higher intrabony defect fill at sites treated with PRF than those treated with open flap debridement alone.

The results in this study were also following the research conducted by Jung et al.<sup>15</sup>, in which PDGF in activated PRF was maintained for three weeks, and the level of TGF- $\beta$  was highest on the first day, decreasing slightly to the seventh day of healing, and then rapidly after that. In

addition, PRF appears to enhance soft tissue regeneration and shorten the periods of wound healing. The limitations in this study included the risk of bacterial contamination of the membranes when stored in the refrigerator. However, these limitations with PRF can be circumvented by sticking to a standard protocol for preparation and preservation.

## CONCLUSIONS

The application of platelet-rich fibrin could improve the collagen density of gingival connective tissue in periodontitis-induced rabbits.

## REFERENCES

1. Hinrichs JE, Kotsakis G. Classification of Diseases and Conditions Affecting the Periodontium. In: Newman MG, et al. Carranza's Clinical Periodontology. 12th ed. Missouri: Saunders; 2015. p. 45-67.
2. Kononen E, Gursoy M, Gursoy UK. Periodontitis: A Multifaceted Disease of Tooth-Supporting Tissues. *J Clin Med* 2019; 8(8): 1135-47. DOI: [10.3390/jcm8081135](https://doi.org/10.3390/jcm8081135)
3. Holde GE, et al. Periodontitis Prevalence and Severity in Adults: A Cross-Sectional Study in Norwegian Circumpolar Communities. *J Periodontology* 2017; 88(10):1-17. DOI: [10.1902/jop.2017.170164](https://doi.org/10.1902/jop.2017.170164)
4. Takei HH, et al. Gingival Surgical Techniques. In: Newman MG, et al. Carranza's Clinical Periodontology. 12th ed. Missouri: Saunders; 2015. p. 576-581.
5. Chatterjee A, et al. Treatment of Periodontal Intrabony Defects Using Autologous Platelet-rich Fibrin and Titanium Platelet-rich Fibrin: A Randomized, Clinical, Comparative Study. *J Investigate Clin Dent*; 2016;0: 1-6. DOI: [10.1111/jicd.12231](https://doi.org/10.1111/jicd.12231)
6. Ghanaati S, et al. Advanced Platelet-rich Fibrin: A New Concept for Cell-Based Tissue Engineering by Means of Inflammatory Cells. *J Oral Implantology* 2014; 40 (6): 679-89. DOI: [10.1563/aaid-joi-D-14-00138](https://doi.org/10.1563/aaid-joi-D-14-00138)
7. KhisteSV, TariRN. Platelet-rich Fibrin as a Biofuel for Tissue Regeneration. *ISRN Biomaterials* 2013; 1-6. DOI: [10.5402/2013/627367](https://doi.org/10.5402/2013/627367)
8. Pradeep AR, et al. Platelet-rich Fibrin Combined with A Porous Hydroxyapatite Graft for the Treatment of Three-wall Intrabony Defects in Chronic Periodontitis: A Randomized Controlled Clinical Trial. *J Periodontol* 2012;87(1): 5-13. DOI: [10.1902/jop.2012.110722](https://doi.org/10.1902/jop.2012.110722)
9. Tunali M, et al. In Vivo Evaluation of Titanium-prepared Platelet-rich Fibrin (T-PRF): A New Platelet Concentrate. *Br J Oral Maxillofac Surg* 2013; 51: 438-443. DOI: [10.1016/j.bjoms.2012.08.003](https://doi.org/10.1016/j.bjoms.2012.08.003)
10. Eren G, Kantarci A, Sculean A, Atilla G (2016) Vascularization After Treatment of Gingival Recession Defects With Platelet-rich Fibrin or Connective Tissue Graft. *Clin Oral Invest* 2015; 20: 2045-53. DOI: [10.1007/s00784-015-1697-8](https://doi.org/10.1007/s00784-015-1697-8)
11. Ehrenfest DMD, Bielecki T, Jimbo R, Barbe G, Del Corso M, Inchingolo F, et al. Do the fibrin architecture and leukocyte content influence the growth factor release of platelet concentrates? An evidence-based answer comparing a pure platelet-rich plasma (P-PRP) gel and a leukocyte- and platelet-rich fibrin (L-PRF) *Curr Pharm Biotechnol* 2012; 13(7):1145-52. DOI: [10.2174/138920112800624382](https://doi.org/10.2174/138920112800624382)
12. Kiani FA, et al. Histological Characterization of Wound Healing of Flank Verses Midline Ovariohysterectomy in Different Age Groups of Cats. *J Clin Pathol Forensic Med* 2014;5(2): 6-16. DOI: [10.5897/JCPFM2013.0048](https://doi.org/10.5897/JCPFM2013.0048)
13. Sari R et al. Platelet-rich Fibrin membranes accelerate open wound healing better than amniotic membranes: A histological study on the proliferation phase. *Wound Med* 2020; 31: 1-14. DOI: <https://doi.org/10.1016/j.wndm.2020.100190>
14. Thorat M, Pradeep AR, Pallavi B. Clinical effect of autologous platelet-rich fibrin in the treatment of intra-bony defects: a controlled clinical trial. *J Clin Periodontol* 2011;38(10):925-32. DOI: [10.1111/j.1600-051X.2011.01760.x](https://doi.org/10.1111/j.1600-051X.2011.01760.x)
15. Jung HS, Bae HS, Hong KS. The Effects of Platelet-rich Fibrin on Osteoblast Proliferation and Differentiation: Effects of Platelet-rich Fibrin on Osteoblasts. *J Dent Hyg Sci* 2013;13(2): 158-164. DOI: [10.1097/SCS.00000000000003396](https://doi.org/10.1097/SCS.00000000000003396)