

Effect of 20% ethanol extract of Subang pineapple gel on oral mucosa incisional wound length

Indah Puti Rahmayani Sabirin^{1*}, Amanda Debora Polii¹, Rahmadaniah Khaerunnisa¹,
Euis Reni Yuslianti¹, Ris Kristiana²

¹Department of Oral Biology, Faculty of Dentistry Jenderal Achmad Yani University, Indonesia

²Department of Pathology Anatomy, Faculty of Medicine Jenderal Achmad Yani University, Indonesia

ABSTRACT

Introduction: Incisional wound in oral mucosa is usually performed during oral surgery but can also be caused by injury. Although wounds can naturally heal, the application of medicine might help accelerate wound healing. Proving the effectiveness of natural ingredients is currently being promoted because Indonesia owns many plants that are used empirically. The use of natural substances is also supported because it is relatively easy to obtain and safe if used properly. Subang Pineapple (*Ananas comosus* L. Merr) is one of the produce of West Java that people consume and empirically use on wounds. Its fruit and core contain active ingredients that affect wound healing, such as bromelain enzyme, flavonoids, saponin, and alkaloids. This study aims to determine the effect of fruit ethanol extract gel of Subang pineapple on Wistar rats oral incisional wound observed from wound length. **Methods:** 25 rats were divided into five groups: baseline, negative control, positive control with 10% povidone-iodine, positive control with Aloclair™ gel, and treatment group with 20% pineapple ethanol extract gel used as wound model on the buccal mucosa. The length of the incisional wound area was examined on days 0, 3, 7, and 14. Measurement of wound length was performed using a periodontal probe. **Results:** The mean of wound length was smaller especially on day 3 in the treatment group. Post-Hoc Mann-Whitney test ($p < 0.05$ considered significant) showed the wound decrease with Subang pineapple extract was better than the negative control ($p = 0.008$) and povidone-iodine group ($p = 0.007$) but didn't show a significant difference with the Aloclair™ gel group ($p = 0.0118$). **Conclusion:** Topical application of pineapple extract affected oral mucosa incisional wound healing and had a potential to accelerate wound closure. Further study with different concentrations and another type of wound can be suggested.

Keywords: incisional wound; pineapple extract; subang pineapple; wound healing

p-ISSN: 1979-0201; e-ISSN: 2549-6212; Available from: <http://jurnal.unpad.ac.id/pjd/article/view/36615>

DOI: [10.24198/pjd.vol34no3.36615](https://doi.org/10.24198/pjd.vol34no3.36615)

Submission: Nov 16, 2021; Accepted: Nov 31, 2022; Published online: Nov 31, 2022

INTRODUCTION

Oral mucosa injuries can occur from physical trauma, cuts, chemical substances, or idiopathic

causes. Physical trauma or cuts can happen intentionally or not, but both can cause loss of tissue continuity in the oral mucosa, which causes discomfort, especially during eating and talking.

*Corresponding author: Indah Puti Rahmayani Sabirin, Department of Oral Biology, Faculty of Dentistry Jenderal Achmad Yani University, Indonesia. Jl. Terusan Jenderal Sudirman PO BOX 148, Cimahi, West Java, Indonesia. Phone: +6285624329427; Email: indah.puti@lecture.unjani.ac.id

Cuts in oral mucosa usually occur on a sterile oral surgery procedure, but this will still cause tissue discontinuity and reduce the mucosa's defence system.^{1,2,3}

Oral mucosa wounds will experience a healing process like in the other part of the body. However, the healing process in the incisional wound is less complex than excisional wounds, although, in both wound types, the same three phases occur. These phases are inflammatory, proliferative, and remodeling phases. The difference especially showed on the proliferative phase on incisional wound since incisional wound does not cause loss of lamina propria under the mucosa epithelium.²

Medications are essential to accelerate wound healing so that the discomfort caused by the injury can be repressed. One of the means of medication is by using herbal medicine. This kind of treatment appeals to the public because of its convenience and safety. Pineapple (*Ananas comosus* L.Merr) is one of the tropical fruits that can be used as medicinal plants for wound healing found easily in Indonesia. Subang pineapple is a West Java produce that has been well known all around the country because of its taste, distinctive size of the fruit, and availability. This variant is also known as Smooth Cayenne in other countries. Subang pineapple is well-known locally as Simadu or honey variety since its sweet taste and aroma. Simadu type is a decent type of pineapple in Indonesia, especially West Java. The supply of Subang pineapple continues to increase because many Subang people choose to cultivate them, so they need to be used by the community not only for consumption. Some empirical uses of pineapple are wound healing, arthritis rheumatoid medication, sore throat, as an anticoagulant, reducing cholesterol, reducing uric acid, and as a bronchitis remedy.^{4,5,6,7,8,9}

Active constituents present in pineapple are bromelain, polyphenols, carotenoid, and flavonoids such as epicatechin, catechin, and gallic acid. Vitamin C, vitamin A, potassium, and calcium are the primary nutrients in pineapple. Previous studies found that pineapple fruit effectively suppressed bacterial growth, accelerated skin wound healing, reduced pain or swelling, decreased clinical signs of inflammation, and had antioxidant properties. Bromelain is

one of particular substances of pineapple that contains enzyme which was reported to have been used to treat inflammation, contusion, and pain from trauma. Bromelain topical application was proved to be safe and effective for treatment and debridement of necrotic tissue on skin wound healing and does not affect natural wound repair activity. This study aims to create formula from Subang pineapple consequently, as a source for wound healing medication which is easy to obtain and with little side effect.^{4,5,6,8,10,11,12}

METHODS

This experimental study used Wistar rats as a standard oral mucosa wound healing process.

Animal

Before the test, all rats were adapted for seven days. Rats were kept in plastic cages measuring 39cm x 42cm x 15cm (length x width x height) and were given a base of husks and woven wire as a cover. They were given softened pellets and water every day. Rats were put into cages randomly consisting of one rat per cage, and each cage was marked according to the group.

Ethanol extract of pineapple (*Ananas comosus* L. Merr)

Subang pineapple for this study was obtained from Mekar Sari Jaya farm in Subang at least 18 months after planting. Ethanol extract gel of Subang pineapple was made by maceration method with ethanol for 72 hours to acquire concentrated liquid extract, and 10 ml liquid extract was combined with 2 ml gel base (CMC-Na) to obtain 20% of pineapple extract gel.

Groups and treatment

Twenty-five Wistar rats were divided into five groups: baseline, negative control, positive control with povidone-iodine, positive control with Aloclair™ gel, and treatment group with 20% ethanol extract gel of Subang pineapple fruit. A 10mm incision with 1mm depth was done in the buccal mucosa surface of each group after a general anaesthetic procedure with ketamine by using a scalpel and measured with a periodontal probe and examined visually. The incision was not performed on the baseline group as it was used

as an evaluation for normal condition. After the incision procedure, the wound was irrigated with distilled water and dried with tampons and no suturing was done on each group. The medication was applied every day on the wound for 14 days

by using sterile cotton pellets. The wound length was observed quantitatively on days 0, 3, 7, and 14 on all groups except the baseline, by using 6-inch stainless steel ruler and periodontal probe, to perform double-check on the wound (Figure 1).

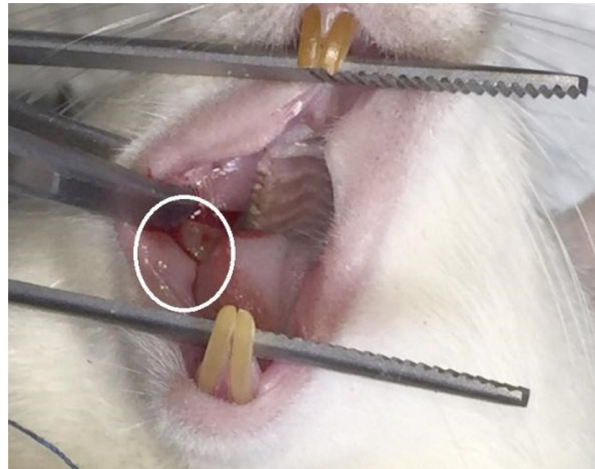


Figure 1. Incisional wound was done on rat's buccal mucosa (shown here in a circle)

Statistical analysis

Wound lengths were measured on days 0, 3, 7, and 14 post incision with a periodontal probe. The mean of the length in incised rat groups was analyzed using the Kruskal-Wallis test since the normality and homogeneity test were not expected, then continued with Mann-Whitney Post Hoc test to find the difference between every two groups.

The study with the animal subject had received ethical clearance from the Health Research Ethics Committee of Faculty of Medicine, Jenderal Achmad Yani University with the number 002/UH1.02/2021. Twenty-five male Wistar rats were maintained in an Animal laboratory on the Faculty of Medicine, Jenderal Achmad Yani University.

RESULTS

Observation of incisional wound healing on Wistar rat buccal mucosa with an application of ethanol extract gel of Subang pineapple showed that in the treatment group, there appeared to be a better decrease of wound length than other groups, especially in the treatment group on day 3. However, on day 7, it showed that the application of Aloclair™ gel as positive control II has the same effect as the pineapple gel extract application. On day 14, the wound all groups had already been closed clinically. The Kruskal-Wallis test was carried on since the normality test result was not expected. The result showed that group wound length measurements had a significant difference only on days 3 and 7.

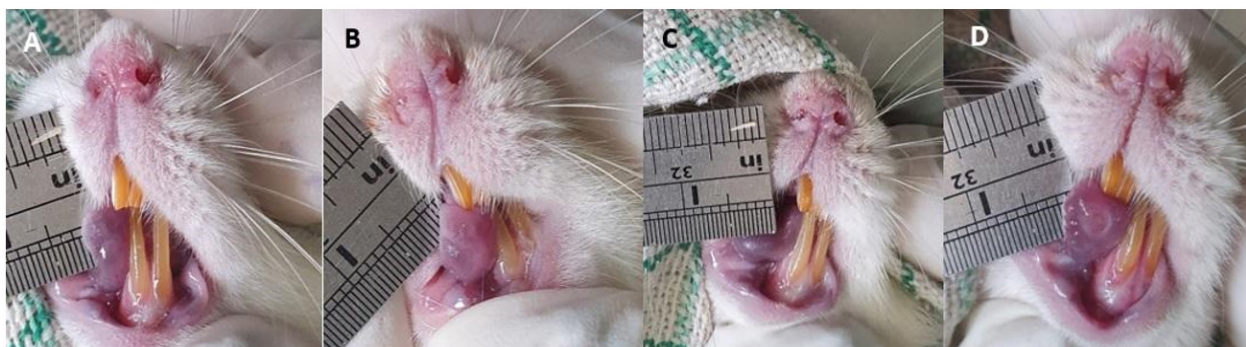

Figure 2. Wound condition on day 3. From left to right: A. Negative control; B. Positive control with povidone iodine; C. Positive control with Aloclair™; D. Treatment group.

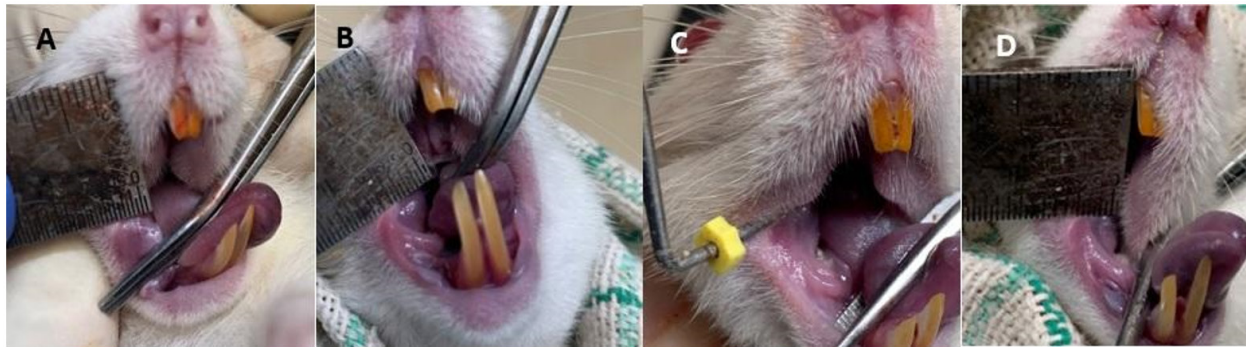


Figure 3. Wound condition on day 7. From left to right: A. Negative control; B. Positive control with povidone iodine; C. Positive control with Aloclair™; D. Treatment group.

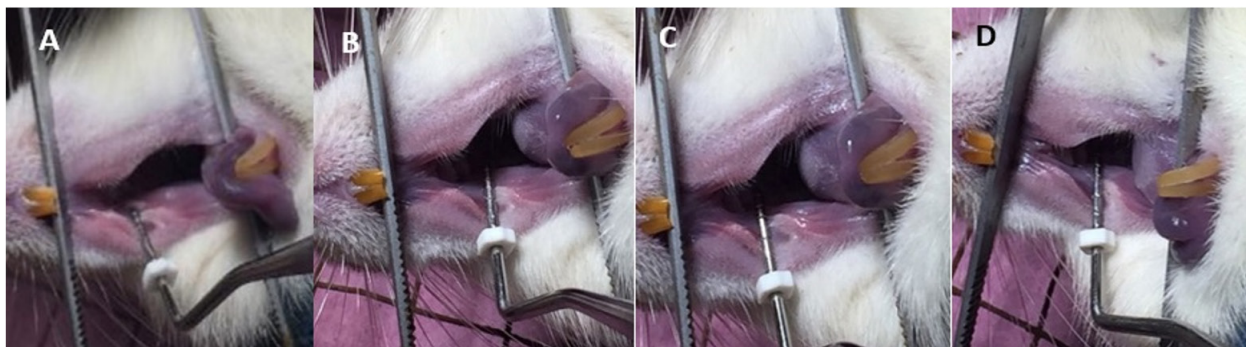


Figure 4. Wound condition on day 14; From left to right: A. negative control group, B. positive control group with povidone-iodine, C. positive control group with Aloclair™ gel, and D. treatment group with 20% ethanol extract of pineapple. All the wound had closed on day 14.

Table 1. Measurement of wound length on days 0. 3. 7. and 14

	Negative control	10% Povidone-iodine	Aloclair™ gel	Pineapple extract gel	P
	Mean diameter (mm)				
Day 0	10	10	10	10	1.000
Day 3	6.2	5.2	3.6	2.8	0.004*
Day 7	1	0.6	0	0	0.044*
Day 14	0	0	0	0	1.000

*Kruskal-Wallis test considered significant ($p < 0.05$)

Table 2. Multiple comparison of wound length on four groups

Group		Day 0	Day 3	Day 7	Day 14
Negative control	Povidone Iodine 10%	1.000	0.054	0.502	1.000
	Aloclair™ gel	1.000	0.008*	0.053	1.000
	Pineapple extract	1.000	0.008*	0.053	1.000
Povidone iodine 10%	Aloclair™ gel	1.000	0.006*	0.050*	1.000
	Pineapple extract	1.000	0.007*	0.050*	1.000
Aloclair™ gel	Pineapple extract	1.000	0.118	1.000	1.000

*Post-Hoc Mann-Whitney test considered significant ($p < 0.05$)

The Post Hoc test result (Table 2) showed a significant difference between the treatment group and other groups except with Aloclair™ application on day 3. However, on the 7th day, the mean wound measurement on the treatment group differed with a negative control without any

medication. On day 14, all groups had experienced wound closure clinically. The wound condition on day 3, 7, and 14 represented on figure 2 to figure 4 subsequently. difference only on days 3 and 7. The Post Hoc test result (Table 2) showed a significant difference between the treatment group and

other groups except with Aloclair™ application on day 3. However, on the 7th day, the mean wound measurement on the treatment group differed with a negative control without any medication. On day 14, all groups had experienced wound closure clinically. The wound condition on day 3, 7, and 14 represented on figure 2 to figure 4 subsequently.

DISCUSSION

This study showed that ethanol extract gel of Subang pineapple in 20% concentration had a more rapid wound healing effect than control groups, especially on days three dan 7. Aloclair™ gel and the povidone-iodine solution was used as a positive control because of their use as first aid on wounds in general. No statistically significant difference between the treatment group and Aloclair™ application showed that in this study, the ability of pineapple ethanol extract had approached the standard of topical mucosa wound medication.

The wound closure on day 14 on all groups showed that on the incisional wound, minimal damage of the mucosa and less connective tissue loss caused the wound to close in two weeks without medication naturally. However, quick wound closure is much better since the discomfort period can also be suppressed and eventually, it can help promote quality of life.

The ethanol extract gel of Subang pineapple can facilitate wound repair by pineapple ethanol extract achieved from active constituents such as flavonoids, vitamin C, bromelain, saponin, carotenoids, and alkaloid, which possibly have effects on wound healing phases through antioxidant, anti-inflammatory, and antimicrobial properties. Those active ingredients in pineapple fruit have very low toxicity based on studies.^{9,10,12,13,14,15}

Bromelain is the main enzyme found in the fruit and stem of the pineapple, which from previous studies were found to have anti-inflammatory, analgesic, fibrinolytic, anti-edematous, and granulation tissue repair properties.^{5,13} Another study of bromelain effect on wound healing also found out that bromelain can help decrease days of postsurgery inflammation, remove damaged or necrotic tissue from wounds by its ability in enzymatic debridement, and accelerate skin

wound healing. Given that this study result showed that the healing effect is more evident on third and seventh day, it can be concluded that the ingredient activity possibly more dominant on inflammatory and proliferative phase of incisal wound.

Anti-inflammatory, analgesic, and proteolytic effects of bromelain has an important role on inflammatory phase as it reduced inflammation and promote debridement of necrotic tissue. Previous studies showed that bromelain acted by reducing bradykinin and prostaglandin E2 levels on the inflammation site as well as TNF- α expression. The bromelain anti-inflammatory effect is also managed by controlling leukocyte cell surface molecules based on prior studies related to chemotaxis, cellular adhesion, and induction of pro-inflammatory cytokines. Proliferative phase consists of new epithelial and granulation tissue establishment and new vascular formation.

The constituent such as bromelain acted on proliferative phase by promoting re-epithelialization, though the mechanism has not explained clearly yet. However, flavonoids on pineapple also possibly performed during this phase. A flavonoid in the plant has been known to have antioxidant, antimicrobial, and wound healing properties. Flavonoids function as tissue repair agents, astringent, and antibacterial in wound healing process.

Epicatechin, catechin, and gallic acid are important flavonoids found in pineapple fruit and stem. Wound healing mechanisms from flavonoids promote collagen synthesis in proliferative phase and reduce MDA and TNF- α levels. Epicatechin also has an effect in decreasing TGF- β as the cytokine that promotes fibrosis to reduce scar formation. Flavonoid performs an antibacterial mechanism by weakening the bacteria pathogenicity, inhibiting the synthesis of bacterial nucleic acid and cytoplasmic membrane function, disrupting energy metabolism, and negative permeability of cell membrane.^{2,3,11,15,16}

Vitamin C is well-known as a potent antioxidant with high bioavailability. Vitamin C promotes collagen synthesis and acts as a co-factor to modify procollagen to collagen in wound healing. Vitamin C allows collagen to accelerate mucosa wound healing during the inflammatory,

proliferative, and remodelling phase.^{17,18}

Saponin and alkaloids on the plant have an antibacterial role. Saponin acts through a saponification mechanism. It also has antibacterial activity against *Pseudomonas aeruginosa*, *Staphylococcus aureus* and oral bacteria like *Streptococcus mutans* as well as inducing phagocytosis.

The Saponin mechanism on bacteria increases the permeability of the cell membrane and eventually causes bacteria cell hemolysis. On the other hand, alkaloids disrupt the cell membrane by damaging the membrane proteins. Carotenoids have antioxidant properties, and it helps protect tissues and cells from free radicals that cause damage and support the immune system.

It can be added that topical medication on wounds aims to heal and protect the tissue, influence the local metabolism process, and help eradicate microorganisms that cause infection. The wound healing rate using topical formula depends on the type of wound, medication and preparation, and its absorption capacity.^{12,14,19,20,21}

CONCLUSION

Ethanol extract gel of Subang pineapple affects incisional wound of Wistar rat oral mucosa. However, a subsequent study using different concentrations, more samples, and other kinds of wounds could be suggested.

REFERENCES

1. Miloro M, Ghali GE, Larsen P. Principles of oral and maxillofacial surgery. 3rd ed. Shelton: PMPH; 2011. p.1-1687.
2. Kumar V, Abbas AK, Fausto N. Robbins and Cotran's pathologic basis of disease. 9th ed. Philadelphia: Saunders; 2014. p.1-1472.
3. Nanci A. Ten Cate's oral histology. St Louis: Elsevier; 2012. p.337-340.
4. Azizan A, Lee AX, Hamid NAA, Maulidiani M, Mediani A, Ghafar SZA, Zolkeflee NKZ, Abas F. Potentially bioactive metabolites from pineapple waste extracts and their antioxidant and alpha-glucosidase inhibitory activities by ¹H NMR. Foods. 2020;9(173):1-19. DOI: [10.3390/foods9020173](https://doi.org/10.3390/foods9020173)
5. Eyarefe OD, Fabiyi BO. Wound healing potentials of aqueous pineapple (*Ananas comosus*) extract - a Preliminary Report. Global J Pharmacol. 2016;10(1):23-30.
6. Kasa T, Fistum G, Madda Y. Chemical composition and nutritional effect of pineapple, mango, banana, avocado and orange: A review article. Chem Proc Eng Res 2017;(54):1-6.
7. Hadiati S, Indriyanti NLP. Technical Instruction of Pineapple Cultivation. 2008. p.1-5.
8. Rasyad AA, Erjon, N. Effects of pineapple (*Ananas comosus* (L.) Merr) extract to lower uric acid levels in hyperuricemic in male rats. J Il Far. 2019;15(2):20, 64-69. DOI: [10.20885/jif.vol15.iss2.art2](https://doi.org/10.20885/jif.vol15.iss2.art2)
9. Kang MH, Kim BH. Oral Wound Healing Effects of Acai Berry Water Extracts in Rat Oral Mucosa. Toxicol Res. 2018;34:97-102. DOI: [10.5487/TR.2018.34.2.097](https://doi.org/10.5487/TR.2018.34.2.097)
10. Muhammad ZA, Ahmad T. Therapeutic uses of pineapple-extracted bromelain in surgical care - A review. J Pak Med Assoc. 2017;67(1):121-125.
11. Hikisz P, Bernasinska-Slomczewska J. Beneficial properties of bromelain. Nutrients. 2021;13(12):4313. DOI: [10.3390/nu13124313](https://doi.org/10.3390/nu13124313)
12. Varilla C, Marcone M, Paiva L, Baptista J. Bromelain, a Group of Pineapple Proteolytic Complex Enzymes (*Ananas comosus*) and Their Possible Therapeutic and Clinical Effects. A Summary. Foods. 2021;10(10):2249. DOI: [10.3390/foods10102249](https://doi.org/10.3390/foods10102249)
13. Pavan R, Jain S, Shraddha, Kumar K. Properties and therapeutic application of bromelain: a review. Biotechnol Res Int. 2012;2012(976203):1-6. DOI: [10.1155/2012/976203](https://doi.org/10.1155/2012/976203)
14. Ferreira EA, Siqueira HE, Boas EVV, Hermes VS, Rios AD. Bioactive compounds and antioxidant activity of pineapple fruit of different cultivars. Rev Bras Frutic. 2016;38(3):146. DOI: [10.1590/0100-29452016146](https://doi.org/10.1590/0100-29452016146)
15. Zharfan RS, Purwono PB, Mustika A. Antimicrobial activity of pineapple (*Ananas comosus* L. Merr) extract against multidrug resistant of *Pseudomonas aeruginosa*: An in vitro study. IndJ Trop Infec Dis, 2017;6(5):118-123. DOI: [10.20473/ijtid.v6i5.4159](https://doi.org/10.20473/ijtid.v6i5.4159)
16. Shahein AA, Hassan WA, Eldahshan OA,

- Wahdan SA, Hanaa-Mansour A, Eldmerdash E. Wound healing properties of green tea extract in excision-wounded rats. *Az J Pharm Sci.* 2017; 56(2): 112-114. DOI: [10.21608/ajps.2017.28464](https://doi.org/10.21608/ajps.2017.28464)
17. XieY, YangW, TangF, ChenX, RenL. Antibacterial activities of flavonoids: structure-activity relationship and mechanism. *Curr Med Chem* 2015;22(1):132-49. DOI: [10.2174/0929867321666140916113443](https://doi.org/10.2174/0929867321666140916113443)
18. Bikker A, Wienders J, van Loo R, Loubert M. Ascorbic acid deficiency impairs wound healing in surgical patients: Four case reports. *Int J Surg Open.* 2016;2:15-18. DOI: [10.1016/j.ijso.2016.02.009](https://doi.org/10.1016/j.ijso.2016.02.009)
19. Mohammed BM, Fisher BJ, Kraskauskas D, Ward S, Wayne JS, Brophy DF, Fowle AA, Yager DR, Natarajan R. Vitamin C promotes wound healing through novel pleiotropic mechanisms. 2016;13(4):572-584. DOI: [10.1111/iwj.12484](https://doi.org/10.1111/iwj.12484)