Case Report

The use of feeding plate to improve weight gain in infants with cleft palate during surgical preparation: a case report

Hidayatullah Hidayatullah[1]
Arlette Suzy Puspa Pertiwi[2]
Machmud Al Husyaerry[3]

[1]Specialist program of Pediatric Dentistry, Universitas Padajdajaran, Bandung, indonesia
[2]Departement of Pediatric Dentistry, Faculty of Dentistry, Universitas Padjadjaran, Bandung-Indonesia
[3]Departement of Pediatric, RS Pandega, Pangandaran, Indonesia

* Correspondence:
hidayatullah22001@@mail.unpad.ac.id

Received: 21 November 2024
Revised: 14 January 2025
Accepted: 20 March 2025
Published: 31 March 2025
DOI: 10.24198/pjd.vol37no1.59313

p-ISSN 1979-0201
e-ISSN 2549-6212

Citation:
Hidayatullah H, Pertiwi ASP, Husyaerry MA.The use of feeding plate to improve weight gain in infants with cleft palate during surgical preparation: a case report. Padj J Dent, April. 2025; 37(1) Supplements 1: 105-110.

ABSTRACT

Introduction: Cleft palate impairs feeding ability in infants, leading to nutritional deficiencies and delayed surgical intervention. Early management is critical to optimize growth parameters. The use of a feeding plate has been shown to significantly enhance feeding efficiency. This facilitates adequate milk intake, reduces the risk of nasal regurgitation and aspiration, and supports consistent weight gain essential for timely surgical repair. This case report aims to evaluate the use of a feeding plate in an infant with cleft palate, focusing on its impact on nutrition and surgical preparation. **Case Report:** An 18-day-old female infant with a Veau class II cleft palate presented with feeding difficulties. A feeding plate was fabricated using an elastomeric impression technique. Following six weeks of plate use, the infant's weight increased from 3.3 kg to 4.6 kg, and feeding efficiency improved markedly with no sign of nasal regurgitation. **Conclusion:** The application of a feeding plate significantly improved nutritional outcomes and enhanced surgical readiness in an infant with cleft palate.

KEYWORDS

Cleft palate, feeding plate, infant nutrition, surgical preparation.

INTRODUCTION

Cleft palate or palatoschisis, is a common congenital abnormality affecting the middle third of the face in infants. This condition occurs when the roof of the mouth does not fully form during fetal development, resulting in a gap between the palate and nasal cavity.[1] Etiological factors include genetic predisposition, environmental influences, hormonal imbalances, nutritional deficiencies, infections, radiation exposure during pregnancy, and maternal consumption of alcohol, tobacco, or teratogenic substances.[2-4]

Feeding difficulties are among the earliest and most critical challenges encountered by infants with cleft palate. Due to an inability to create adequate negative intraoral pressure during suckling, these infants struggle to extract milk effectively. Milk frequently refluxes into the nasal cavity, increasing the risk of aspiration and subsequent respiratory complications.[4,5] As a result, these infants experience prolonged feeding times, insufficient caloric intake, and a heightened risk of malnutrition and stunted growth if not managed promptly. Adequate nutritional support is particularly essential in preparation for cleft palate reconstructive surgery, typically scheduled within the first 18 to 24 months of life.[6,7]

Early intervention is therefore critical to ensure adequate nutritional intake prior to reconstructive surgery. One widely used aid in managing feeding difficulties in these patients is the feeding plate. The feeding plate is typically fabricated from acrylic and designed to cover the cleft palate. Feeding plates are made from safe, non-toxic materials, and are designed to facilitate easier food intake in infants.[6] The device functions as an obturator, closing the cleft palate and enabling improved suction during feeding, thereby reducing the risk of nasal regurgitation.[9]

The application of feeding plates as a breastfeeding aid has demonstrated effectiveness in improving nutritional intake in infants with cleft palate. This intervention not only helps in meeting the nutritional needs of infants but also contributes to optimal growth and development before reconstructive surgery is performed.[10] With appropriate fabrication, feeding plates contribute to the achievement of ideal preoperative weight, with surgical repair generally performed at 3 months of age for cleft lip and between 1.5 to 2 years for cleft palate.[11,12]

This case report is unique in documenting the use of a feeding plate in an infant presenting with both a Veau Class II cleft palate and bronchopneumonia, highlighting effective nutritional rehabilitation despite concurrent respiratory compromise. This case report aims to evaluate the use of a feeding plate in an infant with cleft palate, focusing on its impact on nutritional status and surgical preparedness.

Case Report

An 18-day-old female infant was referred with a chief complaint of feeding difficulties accompanied by nasal regurgitation. Clinical examination revealed a complete cleft of the hard and soft palate, classified as Veau class II, with no evidence of edema or hyperemia (Figure 1). Hematological investigations yielded results within normal reference ranges, while chest radiography demonstrated peripheral infiltrates in the left lung, suggestive of early-stage bronchopneumonia (Figure 2). To address the feeding challenges and enhance nutritional intake, the fabrication of a feeding plate was planned as an interim prosthetic intervention.

The treatment procedure encompassed several stages: impression taking using an elastomeric material with an infant-sized tray under supplemental oxygen to mitigate the risk of anoxia, ensuring an accurate capture of the palatal defect (Figure 3); model preparation and feeding plate fabrication using self-cured acrylic resin, designed to provide comprehensive coverage of the cleft without impinging upon adjacent soft tissues (Figure 4); intraoral try-in and fitting with necessary adjustments to optimize retention, stability, and comfort (Figure 5); parental education regarding insertion, removal, hygiene maintenance, and monitoring for signs of oral irritation or feeding difficulties; and biweekly follow-up evaluations to monitor feeding performance, growth parameters, and to adjust the prosthesis as necessary to accommodate craniofacial development. Ethical approval was obtained from the institutional review board, and written informed consent was secured from the infant's parents prior to initiation of treatment.

Following insertion of the feeding plate, immediate improvements in feeding behavior were noted. The infant exhibited effective suckling with marked reduction in nasal regurgitation. Objective evaluation parameters included: (1) feeding efficiency, assessed by the infant's ability to complete feeding sessions without prolonged pauses, choking, or regurgitation; and (2) comfort assessment, based on the absence of signs of distress such as excessive crying, irritability during feeding, or refusal to feed.

Growth monitoring revealed positive outcomes: at four weeks post-insertion, the infant's weight increased from an initial 3.3 kg to 4.1 kg; by six weeks post-insertion, the weight further increased to 4.6 kg. These evaluation intervals were selected based on established growth assessment milestones in infants with cleft anomalies, where early nutritional optimization is essential for subsequent surgical

eligibility. According to standardized pediatric growth charts, the infant's post-intervention weight trajectory corresponded to the 10th to 25th percentile, a satisfactory outcome given the propensity for growth delays in this patient population.

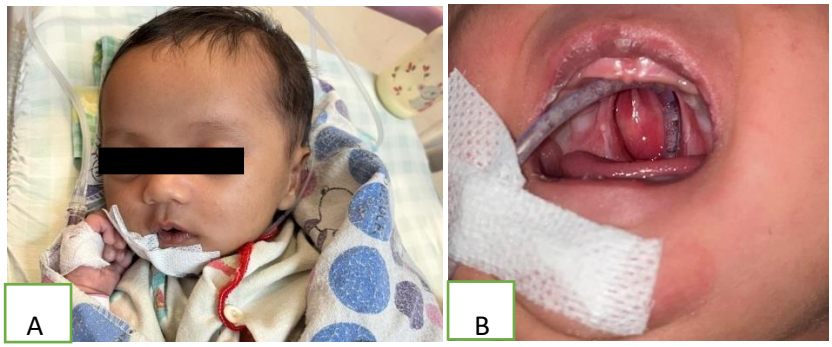

Figure 1. A. 18-day-old infant B. Cleft in the palate

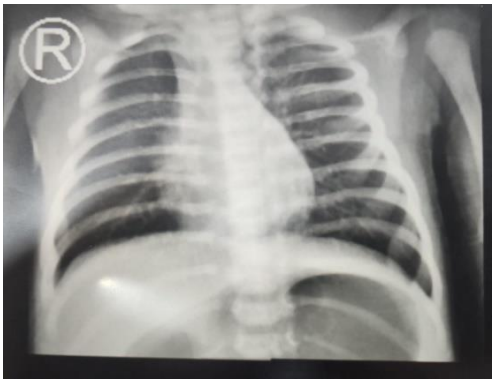

Figure 2. Chest radiograph showing infiltrates (indicated by arrows) in the left peripheral lung area suggestive of bronchopneumonia



Figure 3. Impression results using elastomeric impression material

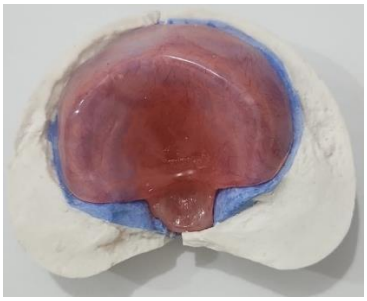

Figure 4. Obturator feeding plate

Throughout the follow-up period, no episodes of aspiration, respiratory distress, or feeding-related complications were documented. Parental reports

corroborated clinical findings, highlighting overall improvements in feeding behavior and greater ease of handling during meal times. These results underscore the efficacy of early prosthodontic intervention in mitigating feeding difficulties and supporting growth in infants with cleft palate anomalies.

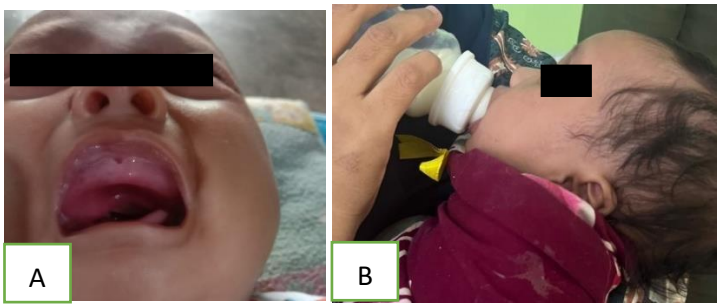

Figure 5. A. Try-in of obturator feeding plate on the infant B. Infant feeding after using the feeding plate

DISCUSSION

The infant in this case presented with a Veau II cleft palate, characterized by a complete separation of the hard and soft palate without signs of local infection. Associated findings included feeding difficulties and nasal regurgitation, but no congenital comorbidities were identified through clinical and radiographic examination. Chest radiography revealed findings consistent with left-sided bronchopneumonia.[10-15]

Feeding difficulties in infants with cleft palate arise primarily due to the inability to create adequate negative intraoral pressure necessary for effective suckling. The anatomical defect prevents proper lip seal and tongue-palate contact, resulting in ineffective milk extraction and frequent nasal regurgitation, which increases the risk of aspiration and respiratory complications. Consequently, feeding sessions become prolonged, caloric intake is insufficient, and nutritional needs are unmet, leading to impaired growth and developmental delays.[13,14,17]

Patients with cleft palate are also prone to Eustachian tube dysfunction due to the abnormal insertion of palatal muscles, increasing their risk for recurrent otitis media, which further complicates feeding and overall health status. If unresolved, these complications may lead to failure to thrive, marked by suboptimal weight gain compared to healthy peers.[18,19,20]

Given these risks, early intervention was initiated. The management timeline included initial clinical and radiographic assessment, fabrication of a feeding plate using elastomeric impressions, prosthesis fitting and adjustment, and systematic biweekly evaluations post-insertion. Following placement of the feeding plate, feeding efficiency improved significantly.[20,21]

The obturator functioned to close the palatal gap, enabling better stabilization of the bottle nipple, facilitating more effective sucking, and reducing milk regurgitation into the nasal cavity. The infant's weight increased from 3.3 kg to 4.1 kg at 4 weeks, and to 4.6 kg at 6 weeks, reflecting catch-up growth commonly observed in cleft-affected infants following early intervention.

Parental education focused on appropriate bottle-feeding techniques rather than direct breastfeeding, as direct breastfeeding is not feasible in infants with wide palatal clefts. Training emphasized infant positioning, feeding duration, and recognition of signs of feeding stress.

Weight gain in infants with cleft palate is a critical determinant of surgical timing. Adequate nutritional status supports improved surgical outcomes by enhancing tissue healing capacity, reducing perioperative morbidity, and minimizing the risk of postoperative complications such as wound dehiscence or fistula formation. In contrast, underweight infants are at increased risk for surgical

delays, prolonged hospitalization, and suboptimal functional and aesthetic outcomes.

Therefore, achieving weight milestones is not only a marker of improved general health but also a prerequisite for safe and effective cleft palate repair.[22-25] A comprehensive management approach—encompassing feeding support, nutritional surveillance, and interdisciplinary coordination— is essential to optimize growth and ensure surgical readiness.[22,23,25]

This case report has several limitations that warrant consideration. It represents the clinical course of a single patient, limiting the generalizability of the findings to the broader population of infants with cleft palate. Further research involving larger cohorts is necessary to validate the effectiveness and generalizability of feeding plate interventions across diverse patient groups with varying severity of cleft anomalies.

CONCLUSION

This clinical case demonstrated that the use of a feeding plate significantly enhanced the infant's ability to feed effectively, leading to improved nutritional intake and weight gain, there by facilitating earlier eligibility for cleft palate surgical repair. These findings reinforce the critical role of early feeding interventions in the multidisciplinary management of infants with cleft palate anomalies. The timely introduction of prosthodontic appliances, such as feeding plates, not only addresses immediate feeding challenges but also supports optimal preoperative growth, which may reduce surgical delays and associated morbidities. Furthermore, structured feeding interventions may have broader implications for enhancing overall developmental outcomes.

The implications of this study suggest that early prosthodontic intervention should be systematically incorporated as a standard practice in the management of cleft palate in infants. Future multicenter studies with extended follow-up periods are recommended to establish robust evidence on the long-term benefits of feeding plate therapy in supporting speech development, maxillofacial growth, and overall psychosocial well-being.

Acknowledgement: No declare
Author Contributions: Conceptualization, H.H; A.S.P.P and M.A.H validation, H.H; A.S.P.P and M.A.H.; investigation, A.S.P.P and M.A.H resources, H.H.; writing original draft preparation, H.H.; writing review and editing, A.S.P.P and M.A.H.; supervision, H.H.; project administration, H.H.; funding acquisition, all authors. All authors have read and agreed to the published version of the manuscript.
Funding: This research received no external funding
Institutional Review Board Statement: The patient has expressed her willingness through the hospital's general consent.
Informed Consent Statement: Written informed consent has been obtained from the patient(s) to publish this paper.
Data Availability Statement: Not applicable.
Conflicts of Interest: The authors declare no conflict of interest.

REFERENCES

1. Hansen PA, Cook NB, Ahmad O. Fabrication of a feeding obturator for infants. Cleft Palate Craniofac J. 2016;53(2):240-244. https://doi.org/10.1597/14-029
2. errano Miranda G, Marques IL, Prietto de Barros S, Arena EP, de Souza L. Weight, length, and body mass index growth of children under 2 years of age with cleft lip and palate. Cleft Palate Craniofac J. 2016;53(3):264-271. https://doi.org/10.1597/14-003
3. Duarte GA, Ramos RB, Cardoso MC. Feeding methods for children with cleft lip and/or palate: a systematic review. Braz J Otorhinolaryngol. 2016;82(5):602-609. https://doi.org/10.1016/j.bjorl.2015.10.020
4. Kaye A, Thaete K, Snell A, Chesser C, Goldak C, Huff H. Initial nutritional assessment of infants with cleft lip and/or palate: interventions and return to birth weight. Cleft Palate Craniofac J. 2017;54(2):127-136. https://doi.org/10.1597/15-163
5. Jadhav R, Nelogi S, Rayannavar S, Patil R. Flexible feeding obturator for early intervention in infants with Pierre Robin sequence. J Prosthet Dent. 2017;118(6):778-782. https://doi.org/10.1016/j.prosdent.2017.01.012
6. Hosseini HR, Kaklamanos EG, Athanasiou AE. Treatment outcomes of presurgical infant orthopedics in patients with nonsyndromic cleft lip and/or palate: a systematic review and meta-analysis of randomized controlled trials. PLoS One. 2017;12(7):e0181768. https://doi.org/10.1371/journal.pone.0181768

7. Bhandari S, Soni BW, Saini SS. From birth till palatoplasty: prosthetic procedural limitations and safeguarding infants with palatal cleft. J Indian Soc Pedod Prev Dent. 2018;36(1):101-105. https://doi.org/10.4103/JISPPD.JISPPD_208_17
8. Moustafa MA, Kandeel AA, Habib AMA, Hassan SA. Feeding obturator as an airway adjunct during complete unilateral cleft palate repair. Indian J Anaesth. 2018;62(5):376-380. https://doi.org/10.4103/ija.IJA_714_17
9. Visser EE, Krüger EE, Margaretha A, Kritzinger AM. Feeding difficulties in infants with unrepaired cleft lip and palate and HIV-exposure. Afr Health Sci. 2018;18(4):1098-1108. https://doi.org/10.4314/ahs.v18i4.31
10. Naveen BH, Prasad RS, Kashinath KR, Kumar S, Kalavathi SD, Laishram N. An innovative modified feeding appliance for an infant with cleft lip and cleft palate: a case report. J Family Med Prim Care. 2019;8(6):2134-2136. https://doi.org/10.4103/jfmpc.jfmpc_327_19
11. Boyce JO, Reilly S, Skeat J, Cahir P; Academy of Breastfeeding Medicine. ABM clinical protocol #17: guidelines for breastfeeding infants with cleft lip, cleft palate, or cleft lip and palate-revised 2019. Breastfeed Med. 2019;14(7):437-444. https://doi.org/10.1089/bfm.2019.29132.job
12. Wijekoon P, Herath T, Mahendran R. Awareness of feeding, growth and development among mothers of infants with cleft lip and/or palate. Heliyon. 2019;5(12):e02900. https://doi.org/10.1016/j.heliyon.2019.e02900
13. Kucukguven A, Calis M, Ozgur F. Assessment of nutrition and feeding interventions in Turkish infants with cleft lip and/or palate. J Pediatr Nurs. 2020;51:e39-e44. https://doi.org/10.1016/j.pedn.2019.05.024
14. Tirupathi SP, Ragulakollu R, Reddy V. Single-visit feeding obturator fabrication in infants with cleft lip and palate: a case series and narrative review of literature. Int J Clin Pediatr Dent. 2020;13(2):186-191. doi:10.5005/jp-journals-10005-1723. https://doi.org/10.5005/jp-journals-10005-1723
15. Murthy PS, Deshmukh S, Murthy S. Assisted breastfeeding technique to improve knowledge, attitude, and practices of mothers with cleft lip- and palate-affected infants: a randomized trial. Spec Care Dentist. 2020;40(3):273-279. https://doi.org/10.1111/scd.12464
16. Chattopadhyay D, Vathulya M, Naithani M, Jayaprakash PA, Palepu S, Bandyopadhyay A, et al. Frequency of anemia and micronutrient deficiency among children with cleft lip and palate: a single-center cross-sectional study from Uttarakhand, India. Arch Craniofac Surg. 2021;22(1):33-37. https://doi.org/10.7181/acfs.2020.00472
17. Madhoun LL, Crerand CE, O'Brien M, Baylis AL. Feeding and growth in infants with cleft lip and/or palate: relationships with maternal distress. Cleft Palate Craniofac J. 2021;58(4):470-478. https://doi.org/10.1177/1055665620956873
18. Gallego Sobrino R, Iglesia-Altaba I, Moreno-Aznar LA, Rodríguez G. Long-term growth patterns in children born with cleft lip and/or palate: a systematic review. Nutr Hosp. 2021;38(2):410-417. https://doi.org/10.20960/nh.03426
19. Green MA, Resnick CM. Feeding considerations for infants with craniofacial malformations. Semin Fetal Neonatal Med. 2021;26(6):101280. https://doi.org/10.1016/j.siny.2021.101280
20. Penny C, McGuire C, Bezuhly M. A systematic review of feeding interventions for infants with cleft palate. Cleft Palate Craniofac J. 2022;59(12):1527-1536. https://doi.org/10.1177/10556656211051216
21. Ueki S, Fujita A, Kumagai Y, Hirai Y, Tashiro E, Miyata J. Bottle-feeding techniques for children with cleft lip and palate experiencing feeding difficulties. Int J Nurs Sci. 2023;10(1):82-88. https://doi.org/10.1016/j.ijnss.2022.12.004
22. Gallego Sobrino R, Iglesia-Altaba I, Moral I, Iso I, Delso E, Rodríguez G. Growth trajectories in children with cleft lip and/or palate. Nutr Hosp. 2023;40(4):717-723. https://doi.org/10.20960/nh.04620
23. Ogawa A, et al. An investigation into nutritional methods at the fifth day after birth of infants in association with cleft type and laterality. Congenit Anom (Kyoto). 2023;63(3):74-78. https://doi.org/10.1111/cga.12509
24. Williams JL, Kotlarek KJ. Current post-operative feeding practices following surgical repairs for infants with cleft palate. J Craniofac Surg. 2023;34(7):2142-2145. https://doi.org/10.1097/SCS.0000000000009586
25. Williams JL, Lien KM, Kirschner R, Allen G, Chapman K; Cleft Outcomes Research NETwork (CORNET) Consortium. Feeding management and palate repair timing in infants with cleft palate with and without Pierre Robin sequence: a multisite study. Cleft Palate Craniofac J. 2025;62(7):1180-1189. https://doi.org/10.1177/10556656241239766

https://doi.org/10.24198/pjd.vol37no1.59313 Copyright: © 2025 by Padjadjaran Journal of Dentistry. Submitted to Padjadjaran Journal of Dentistry for possible open access publication under the terms and conditions of the Creative Commons Attribution (CC BY) license (https:// creativecommons.org/licenses/by/ 4.0/).