PJDRS

Padjadjaran Journal of Dental Researchers and Students

Journal homepage: https://jurnal.unpad.ac.id/pjdrs
p-ISSN: 2656-9868 e-ISSN: 2656-985X

Scoping Review

Pre-implant assessment of alveolar bone density using dental radiographs and DEXA: a scoping review

Farina Pramanik[1*], Rafiqah Rezky Amelia Jamaluddin[2] Rifarana Inayah Dhiaulhaq[2], Lulu Hervina Gani[2] Christandi Prana Yuwana[2], Sufiyani Husnah[2] Daisy Wulansari[3], Jamas Ari Anggraini[4] ,Cortino Sukotjo[5]

[1]Department of Dentomaxillofacial Radiology, Faculty of Dentistry, Universitas Padjadjaran, Bandung, Indonesia,
[2]Dentomaxillofacial Radiology Residency Program, Faculty of Dentistry, Universitas Padjadjaran Bandung, Indonesia,
[3]Department of Prosthodontics, Faculty of Dentistry, Universitas Padjadjaran, Bandung, Indonesia
[4]Department of Oral Biology, Faculty of Dentistry, Universitas Padjadjaran, Bandung, Indonesia
[5]Department of Restorative Dentistry, University of Illinois, Chicago, USA

*Correspondence
farina.pramanik@unpad.ac.id

Submitted | 08 August 2025
Revised | 12 August 2025
Accepted | 27 September 2025
Published | 31 October 2025
DOI: 10.24198/pjdrs.v9i3.65953

ABSTRAK

Introduction: Implant stability is strongly influenced by alveolar bone density, as higher density enhances primary stability and supports long-term osseointegration, making its evaluation a crucial component in presurgical planning. Radiological assessment offers a readily available, non-invasive approach for evaluating bone quality prior to implant placement. Commonly used imaging modalities include periapical, panoramic, and cone-beam computed tomography (CBCT), while dual-energy X-ray absorptiometry (DEXA) remains the gold standard for measuring bone mineral density. This review aims to assess alveolar bone density before dental implant placement using periapical, panoramic, CBCT, and DEXA. **Methods:** A scoping review was conducted across Science Direct, PubMed, PMC, Semantic Scholar, and Google Scholar using the search terms "Alveolar bone, density, presurgical, dental implant, radiograph". Inclusion and exclusion criteria were applied to 408 retrieved records, yielding 17 relevant articles for analysis. **Results:** Multiple radiographic methods and measurement protocols were identified. Of the 17 included studies, 7 utilized CBCT, 2 panoramic, 2 periapical, 3 DEXA, and 3 combined modalities. Findings indicated that the mandibular bone, particularly in the anterior region, generally exhibits higher density than the maxillary sites. Substantial variability was noted in measurement techniques, reference points, and units, including HU, g/cm³, mmAleq, and GV. **Conclusion:** Radiographic evaluation of alveolar bone density is essential for implant treatment planning. CBCT emerged as the most widely used and informative modality. Studies show that the anterior mandibular region has the highest bone density among other regions, thereby affecting implant stability.

KATA KUNCI: Densitas tulang alveolar, CBCT, DEXA, panoramik, periapikal, radiografi

Penilaian densitas tulang alveolar sebelum perawatan implant menggunakan radiografi dental dan DEXA: a scoping review

ABSTRACT

Pendahuluan: *Stabilitas implan sangat dipengaruhi oleh densitas tulang alveolar, dimana densitas tulang yang tinggi akan meningkatkan stabilitas primer implan dan mendukung osseointegrasi, sehingga evaluasi densitas tulang merupakan tahap yang penting sebelum dilakukan pembedahan. Pemeriksaan radiografi untuk evaluasi kualitas tulang merupakan prosedur yang penting dalam perencanaan sebelum pembedahan implan, oleh karena mudah didapatkan dan tidak bersifat invasif. Radiografi periapikal, panoramik dan CBCT merupakan teknik yang paling sering digunakan untuk mengevaluasi kualitas tulang pada perawatan implant. Sedangkan, DEXA merupakan metode gold standard untuk mengukur densitas mineral tulang. Jurnal ini bertujuan untuk menilai densitas tulang sebelum pemasangan implan, menggunakan radiografi periapikal, panoramik, CBCT dan DEXA.* ***Metode:*** *Scoping review ini menggunakan database seperti Science Direct, PubMed, PMC, Semantic Scholar, dan Google Scholar, menggunakan kata kunci: "Alveolar bone, density, presurgical, dental implant, and radiograph". Pencarian mendapatkan 408 artikel, dan total 17 artikel yang digunakan pada jurnal ini.* ***Hasil:*** *Berbagai pemeriksaan radiografi dapat digunakan untuk mengevaluasi densitas tulang. Dari total 17 artikel, 7 artikel menggunakan CBCT, 2 panoramik, 3 DEXA, dan 3 menggabungkan 2 modalitas. Hasil penelitian menemukan bahwa mandibula, terutama pada anterior, memiliki densitas tulang yang lebih tinggi dibandingkan maksila. Dari berbagai artikel ini juga didapatkan beberapa perbedaan dalam teknik pengukuran, titik referensi, dan satuan (HU, g/cm³, mmAleq, GV).* ***Simpulan:*** *Pemeriksaan radiografi untuk mengukur densitas tulang alveolar merupakan teknik yang penting dalam menentukan rencana perawatan implant, dengan CBCT menjadi modalitas yang paling sering digunakan dan memberikan informasi yang paling banyak. Penelitian menunjukkan regio anterior mandibula memiliki densitas tulang yang paling tinggi di antara regio lainnya, sehingga mempengaruhi stabilitas implan*

KEYWORDS: *Alveolar bone density, CBCT, DEXA, panoramic, periapical, radiograph*

Citation: Pramanik F, Jamaluddin RRA, Dhiaulhaq RI, Gani LH, Yuwana CP, Husnah S, Wulansari D, Anggraini JA, Sukotjo C. Penilaian densitas tulang alveolar sebelum perawatan implant menggunakan radiografi dental dan DEXA: a scoping review. Padjadjaran Journal of Dental Researchers and Students. 2025;9:(3)269-280. DOI: 10.24198/pjdrs.v9i3.65953.
Copyright: © 2025 by the authors. Submitted to Padjadjaran Journal of Dental Researchers and Students for possible open access publication under the terms and conditions of the Creative Commons Attribution (CC BY) license (https:// creativecommons.org/licenses/by/ 4.0/).

INTRODUCTION

The prevalence of individuals with missing teeth has been on the rise, correlating with the growing elderly population. Dental implants are a frequently employed treatment option for partially or completely edentulous patients, offering a favorable prognosis in restoring both aesthetics and masticatory function.[1–4] A dental implant serves as a biocompatible substitute for a tooth root, integrated into the mandibular or maxillary bone to provide support for a dental prosthesis.[5] Successful dental implant integration is contingent upon several factors, encompassing the proficiency of the operating surgeon, the patient's adherence to postoperative oral hygiene protocols, and the specific design or surface characteristics of the dental implant.[1] Additionally, the ability of the implant to integrate gradually with adjacent tissues, a process known as osseointegration, is critical for its successful function.[3,5]

Osseointegration is characterized by direct contact between the bone and the implant surface, without any intervening fibrous tissue.[5] To be deemed fully osseointegrated, endosseous implants must meet specific criteria, including marginal bone loss of less than 1 mm in the initial year and less than 0.2 mm annually thereafter after implant placement, alongside the absence of peri-implantitis, implant mobility, patient discomfort, infection, or paresthesia.[4] The most crucial factors for achieving good osseointegration and successful implant treatment are the degree of implant stability.[6–8] Implant stability is a combination of mechanical and biological stability. Primary implant stability is achieved through the mechanical pressure exerted by surrounding bone tissues during implant placement, while secondary implant stability arises from new bone cell formation at the implant surface during the process of osseointegration.[7]

The most important factor in primary stability is the quality and quantity of local bone. Bone quantity refers to the available bone volume at the prospective implant site, which guides the clinician in selecting the appropriate implant dimensions. In contrast, bone quality is characterized by the bone's physiology, degree of mineralization, morphology, and trabecular pattern. [7,9–11] The quality of bone has a critical influence on the surgical approach, healing duration, and timing of prosthetic loading during the implant rehabilitation process. Therefore, assessing bone quality is strongly advised during the presurgical implant planning stage.[2,10,12]

Bone density serves as an objective measure to characterize bone quality, which is characterized by the relative size of the marrow space within a bone unit.[5,13] For instance, the mandible demonstrates a higher proportion of compact to cancellous bone than the maxilla. Clinical research indicates that implants tend to have better long-term survival in the mandible than in the maxilla because the initial stability of an implant is lower in low-density bone compared to high-density bone.[4] Moreover, fractal analysis is another technique used to evaluate bone quality. This non-invasive approach provides a quantitative assessment of complex patterned geometric designs present throughout the image. A decline in the fractal dimension value signifies a simpler structure, whereas an increase suggests a more complex patterned structure.[14]

Direct assessment of bone quality typically involves ex vivo examinations (e.g., dry skulls or cadaveric specimens) or biopsy samples obtained from animal or human subjects, whereas indirect assessment relies on radiographic imaging in living patients.[15] Radiological assessment of bone quality should be a crucial component of presurgical implant planning, as it is a readily accessible and relatively non-invasive approach. Periapical, panoramic, and cone-beam computed tomography (CBCT) radiographic modalities are commonly utilized for the evaluation of bone quality during the presurgical planning phase for dental implant treatment.[7]

These various radiographic techniques possess their own distinct strengths and limitations in assessing the bone characteristics at the prospective implant site. In addition, bone density evaluation is also important in the context of post-implant rehabilitation in both extremities and the oral cavity. DEXA (Dual-Energy X-ray Absorptiometry) is considered the gold standard method for measuring bone mineral density.

The assessment of bone mineral density (BMD) using DEXA has significant clinical relevance in dental implantology, particularly in the presurgical phase. Bone density is a critical determinant of primary implant stability, which strongly influences the process of osseointegration and the long-term success of the implant.

DEXA provides an objective and standardized measurement of bone density that can help identify patients at risk of low bone quality, such as those with osteopenia or osteoporosis, before implant placement. By evaluating site-specific bone density, clinicians can adjust the surgical protocol, implant selection, and loading strategy to optimize treatment outcomes. Thus, DEXA serves as an important adjunct in presurgical planning, supporting evidence-based decision-making in implant dentistry. However, its accuracy can be affected by the presence of metal implants that cause artifacts, patient positioning during scanning, and variability in software processing. These limitations have led to various studies focusing on patients with amputations, dental implants, and total knee arthroplasty (TKA) to explore strategies for minimizing such errors.

No previous review has synthesized the assessment of alveolar bone density assessment across periapical, panoramic, CBCT, and DEXA imaging modalities. This scoping review addresses that gap by mapping current methodologies, identifying inconsistencies in measurement techniques, and highlighting the need for standardized radiographic protocols in presurgical implant evaluation. Therefore, this literature study aims to assess the alveolar bone density prior to dental implant placement, utilizing periapical, panoramic, cone beam computed tomography (CBCT), and DEXA radiographic techniques.[15–17]

METHODS

This study employed a scoping review with a qualitative-descriptive research approach. An electronic search was conducted across several academic databases, including Science Direct, PubMed, PMC, Semantic Scholar, and Google Scholar. The search strategy utilized the following keywords: alveolar bone, density, presurgical, dental implant, and radiograph. All retrieved articles were initially screened based on title and abstract. The data obtained from this screening process were then further filtered and assessed for eligibility for inclusion in the review.

Research topics were determined through questions using PICO: Population (patients scheduled to undergo implant placement), Intervention (periapical, panoramic, CBCT, or DEXA radiographs), Comparison (none), and Outcome (bone density value). The eligibility criteria for this scoping review included original research articles published in English between 2015 and 2025, involving healthy patients without systemic diseases or medication use, and who had not undergone prior bone grafting procedures. Bone density had to be evaluated prior to dental implant placement using periapical, panoramic, CBCT imaging or DEXA bone scan modalities. Articles were excluded if they were case studies, reviews, unpublished, or inaccessible; studies were also excluded if they assessed bone density after implant placement or used imaging modalities other than the specified radiographic techniques.

This review summarizes the key information extracted from the included studies, such as the authors, publication year, study title, country of origin, methodology used to evaluate bone density, sample characteristics, reference points, and the reported findings.

The risk-of-bias assessment indicates that most cross-sectional studies demonstrated strong methodological quality, with clear inclusion criteria, adequate description of study settings, and valid, reliable measurement of both exposure and outcomes. Appropriate statistical analysis was consistently reported. However, notable limitations were observed in the handling of confounding factors, as many studies failed to describe strategies to manage them, and several provided unclear identification of potential confounders. Overall, despite these specific weaknesses, the predominance of low-risk judgments across major domains suggests that the included studies possess generally acceptable methodological rigor (figure1).

The risk-of-bias assessment for the cohort studies shows that most methodological domains were rated as low risk, particularly those related to statistical analysis, measurement of exposure and outcomes, and the adequacy of follow-up duration. The

included studies generally demonstrated valid and reliable measurement procedures and maintained comparable groups at baseline. However, substantial limitations were observed in confounder management, as many studies neither identified potential confounding variables nor reported strategies to address them, resulting in a predominance of "No" ratings in these domains. Additionally, incomplete follow-up strategies and group comparability regarding exposure showed mixed ratings, with several studies classified as unclear or not applicable. Overall, despite these weaknesses, particularly in confounding control, the studies largely exhibited acceptable methodological rigor (Figure 2).

RESULTS

The search and screening is summarized in the PRISMA-ScR flow diagram (Figure 1). An initial electronic search identified 382 articles after removing duplicates. Of these, 35 articles were selected for full-text assessment based on their titles and abstracts meeting the inclusion criteria. Subsequently, 18 articles were excluded for various reasons. Ultimately, 17 articles were deemed eligible for inclusion in this scoping review (Figure 1).

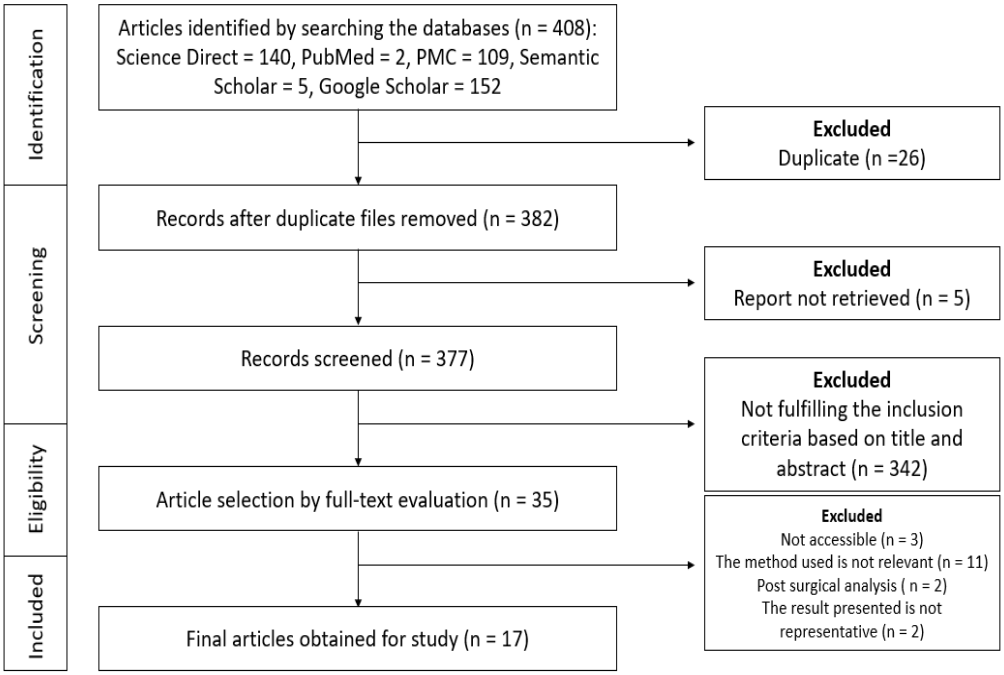

Figure 1. Study selection according to PRISMA-ScR

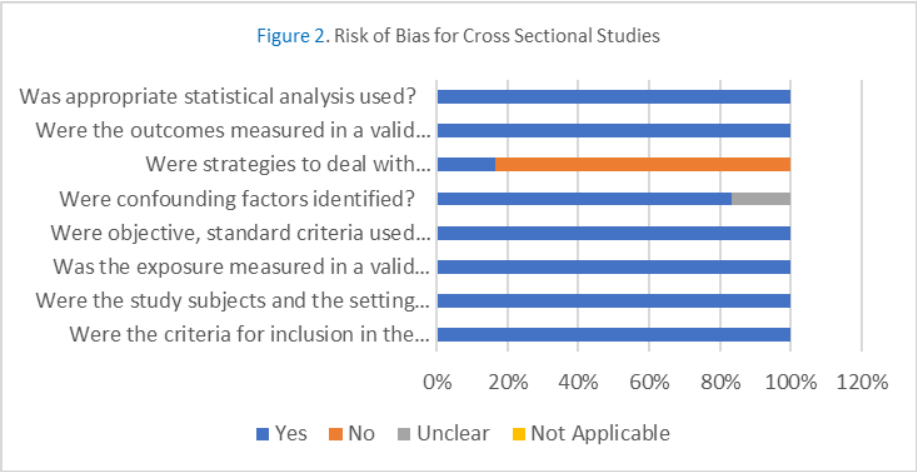

Figure 2. Risk of bias for cross sectional studies

Overall, despite these specific weaknesses, the predominance of low-risk judgments across major domains suggests that the included studies possess generally acceptable methodological rigor (Figure 2). Overall, despite these weaknesses, particularly in confounding control, the studies largely exhibited acceptable methodological rigor (Figure 3).

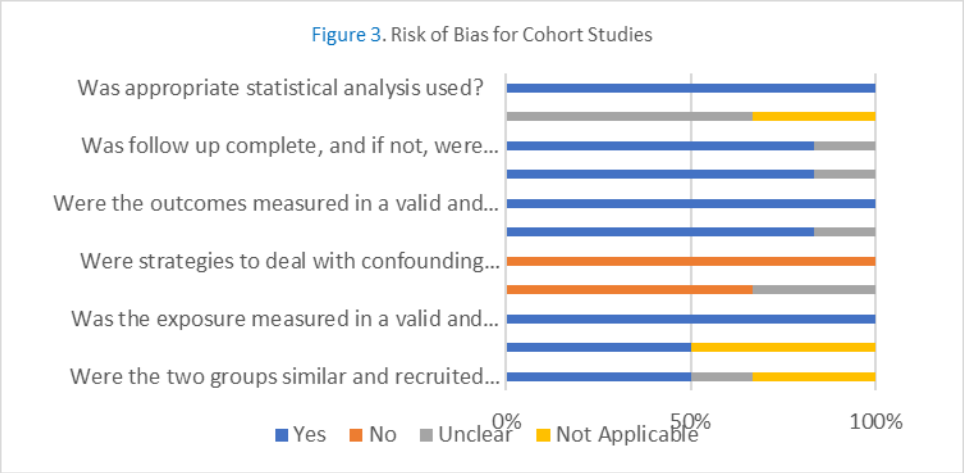

Figure 3. Risk of bias for cohort studies

This scoping review included a wide range of study designs and geographic locations for assessing alveolar bone density at prospective dental implant sites. The included research encompasses observational, retrospective, longitudinal, and cross-sectional designs, reflecting diverse methodological approaches. Geographically, studies originated from Asia, the Middle East, South America, North America, and Europe, underscoring broad international interest in evaluating bone quality for dental implant planning. According to the Scopus journal ranking system, four publications were classified as Quartile 1, three as Quartile 2, and one as Quartile 3, while the remaining journals lack a listed Scopus quartile classification. (Table 1).

Periapical radiographic examination was employed in three of the included studies to assess alveolar bone density, while panoramic radiography was utilized in four others. Notably, CBCT emerged as the most widely adopted technique, appearing in eight of the articles included in the review. The reviewed studies employed two primary approaches to assess alveolar bone density: direct assessment of bone specimens through radiographic imaging, and indirect assessment using radiographs of the jaws. Specifically, two studies directly evaluated alveolar bone density by analyzing radiographs of bone samples, while one study compared the alveolar bone density assessments obtained from jaw radiographs and bone specimen radiographs. The remaining publications in the review utilized radiographic imaging of the patients' jaws to assess alveolar bone density (Table 1).

Table 1. Characteristics of the studies and article summaries

Author (year)	Nationality	Study Design	Scopus Quartile	Method to assess the bone density	Sample type and size	Reference points	Results		
Chugh et al.,[9]	India	Observational	Q1	Panoramic	20 participants older than 18 years	The mesial and distal aspects of right and left permanent first molars and canines and the interproximal area of the central incisors in the maxilla and mandible	Maxilla	669.38 ± 233.17	HU
							Mandible	678.71 ± 209.11	HU

Al-fakeh et al.,[18]	China	Retrospective	Q1	CBCT	65 patients, age from 25 to 74 years	Posterior teeth of the maxillary and mandibular jaws, in three-point 3, 6, and 9 mm under the crestal bone's point, bucally and lingually	BBD at CB3	615.02 ± 292.07	HU
							BBD at CB6	777.87 ± 390.54	HU
							BBD at CB9	718.52 ± 487.93	HU
							LBD at CB3	528.56 ± 298.51	HU
							LBD at CB6	637.84 ± 361.27	HU
							LBD at CB9	667.73 ± 355.21	HU
Jha et al.,[19]	India	Longitudinal		CBCT	20 patients, age wasn't mentioned	Implant site, with 1 mm buccolingual slices (area ranging from 25-30 mm2)	Mean ± SD	869.30 ± 148.346	HU
Hayek et al.,[20]	Lebanon	Observational		Periapical	50 implants from male patients, ange range between 20 and 50	ROI of 25 pixels x 50 pixels at the implant sites	Maxillary Molar	0.297	g/cm3
							Maxillary Premolar	0.305	g/cm3
							Mandibular Molar	0.379	g/cm3
							Mandibular Premolar	0.489	g/cm3
Choi et al.,[21]	USA	Observational	Q1	CBCT	21 bone specimens from 18 participants mean age of 52,9 yeas	Specimens of 3mm diameter and 8-10 mm length was retrieved from implant sites	Mean ± SD	412.81 ± 121.50	HU
Suer et al.,[22]	Turkey	Retrospective		Panoramic	30 patients, with a mean age of 42,2 ± 10,62 years	ROI was selected as an area with diameter and length each 0,5 mm larger than implant size	Mean ± SD	1.74 ± 0.026	g/cm3
Magat, Sener.,[10]	Turkey	Observational	Q2	Panoramic	30 dry human edentulous hemimandibles specimens	ROI of 50 x 50 pixels avoided crestal bone, remaining tooth root and lamina dura	Mean ± SD	1.25 ± 0.11	g/cm3
				CBCT			Mean ± SD	1.13 ± 0.11	g/cm3
Oliveira et al.,[23]	Brazil	Observational	Q2	Periapical	36 healthy patients age between 20 and 75 years	Implant sites	Posterior region of the maxilla	2.38 ± 1.06	mmAleq
							Posterior region of the mandible	3.84 ± 0.68	mmAleq
							Anterior region of the maxilla	5.42 ± 1.57	mmAleq
							Anterior region of the mandible	6.16 ± 1.60	mmAleq
				Panoramic			Posterior region of the maxilla	4.08 ± 2.35	mmAleq

							Posterior region of the mandible	5.34 ± 4.53	mmAleq
							Anterior region of the maxilla	5.15 ± 2.35	mmAleq
							Anterior region of the mandible	5.40 ± 3.29	mmAleq
Poedjiastoeti et al.,[24]	Indonesia	Cross sectional		CBCT	93 patients with minimum age of 20 years old	Implant sites	Maxillary Anterior	362.4 ± 107.35	HU
							Maxillary Premolar	326.6 ± 77.12	HU
							Maxillary Molar	322.0 ± 103.21	HU
							Mandibular Anterior	557.8 ± 160.29	HU
							Mandibular Premolar	402.8 ± 111.06	HU
							Mandibular Molar	408.6 ± 95.87	HU
Hayek et al.,[25]	Lebanon	Observational	Q3	Periapical	50 male participants, age from 20-50 years	Edentulous implant sites with ROI of 25x50 pixels	Maxillary Posterior Region	1.52	g/cm3
							Mandibular Posterior Region	1.553	g/cm3
						Specimens of 2mm diameter and 7mm length was retrieved from implant sites	Maxillary Posterior Region	1.472	g/cm3
							Mandibular Posterior Region	1.499	g/cm3
Oliveros et al.,[26]	Spain	Observational	Q2	CBCT	160 implant sites from 48 patients, age from 31-64 years	Area of implant placement	Posterior Maxilla	590.22 ± 233.48	HU
							Anterior Maxilla	809.38 ± 205.93	HU
							Posterior Mandible	778.66 ± 287.39	HU
							Anterior Mandible	1062.50 ± 167.83	HU
						0,5 mm outside the area of implant placement	Posterior Maxilla	668.48 ± 210.39	HU
							Anterior Maxilla	921.88 ± 202.46	HU
							Posterior Mandible	917.68 ± 271.98	HU
							Anterior Mandible	1221.87 ± 195.76	HU
Issa et al.,[7]	Syria	Longitudinal		CBCT	28 implant sites from 14 adult patients, age between 20 and 50 years	Three areas around the implant: apex, body and neck	Apex	148.17 ± 24.82	GV
							Body	143.50 ± 23.65	GV
							Neck	124.58 ± 22.81	GV
Wang et al.,[6]	Taiwan	Retrospective	Q1	CBCT	300 CBCT images from 127 patients, age between 20 and 85 years	Three ROI methods at the implant sites: rectangle (W: 3,5 mm, L: 11 mm), cylinder (D:	Rectangle	497.0 ± 236.7	GV
							Cylinder	493.9 ± 231.2	GV

						3,5 mm, L: 11 mm), and surrounding cylinder	Surrounding cylinder	523.6 ± 228.0	GV
Harper et al.,[27]	US	Cross sectional	Q1	DEXA (spine and femur)	Adults with knee replacement (n=1000)	Contralateral femur	Femur	L Leg ± 1387 R Leg ± 1777	g/cm³
Monge et al.,[28]	Spain	Longitudinal	Q2	DEXA (lumbar & femoral)	Amputees with osseointegrated implants (n=10)	Non-implanted limb	Tibia	L or R Leg (~1.2–1.4)	g/cm³
Hansen et al.,[29]	Denmark	Ex Vivo Study	Q2	DEXA	Amputees with transfemoral implant (n=20)	Femoral regions	Femur	0.031-0.047	g/cm³
Merheb et al.,[30]	Belgia	Clinical Study	Q1	Panoramic + DEXA	73 osteoporosis patients	Mandibular molar zone	Mandible	0.80–1.0	g/cm³

CBCT was the most commonly used modality, appearing in studies from China, India, the USA, Indonesia, Spain, Syria, and Taiwan, owing to its precision in providing Hounsfield Unit (HU) or grayscale value (GV) measurements. Bone density measurements varied significantly by region. For instance, Oliveros et al.[26] in Spain found the highest HU values in the anterior mandible (1062.50 HU), while Issa et al. (2024) in Syria reported lower grayscale values, particularly at the implant neck (124.58 GV).

In contrast, panoramic radiography, used in studies from India and Turkey, yielded results expressed in HU or g/cm³. Notably, Suer et al.[22] reported one of the highest densities using this method (1.74 g/cm³), illustrating possible variability due to image resolution and ROI selection.

Periapical radiographs, utilized by Hayek et al.[20,25] and Oliveira et al.[23], provided measurements in both g/cm³ and mmAleq (aluminum equivalent millimeters). Oliveira's study showed the highest bone density in the anterior mandible (6.16 mmAleq).

Sample sizes across studies ranged from 14 participants to 127 patients, with age groups spanning from young adults to elderly populations. Reference points for measurement varied, including implant apex, body, and neck, or specific tooth regions such as molars, premolars, and incisors. Across studies, mandibular regions consistently exhibited higher bone density than maxillary regions, and anterior sites tended to exhibit higher values compared to posterior sites.

DEXA measurements demonstrated substantial variability in bone mineral density (BMD) values across anatomical sites and patient populations. Harper et al.[27] reported contralateral femur densities in adults with knee replacements of approximately 1.387 ± 1.777 g/cm³, while Monge et al.[28] observed tibial BMD values of ~1.2 to 1.4 g/cm³ in the non-implanted limb of amputees with osseointegrated implants. Hansen et al.[29] recorded markedly lower femoral BMD values (0.031–0.047 g/cm³) in transfemoral amputees, reflecting significant localized bone loss. In contrast, Merheb et al.,[30] using combined panoramic radiography and DEXA, measured mandibular bone density in osteoporotic patients between 0.80 and 1.0 g/cm³. These findings suggest that DEXA accuracy is highly dependent on anatomical location and patient condition, emphasizing the need for standardized scanning protocols and calibration adjustments to enhance measurement precision in presurgical bone density evaluation.

DISCUSSION

Evaluating alveolar bone density is a critical component of presurgical planning for dental implants, as it directly influences primary implant stability and long-term osseointegration success. As dental implants continue to be a widely accepted treatment for edentulous and partially edentulous patients, reliable preoperative assessment of bone quality becomes increasingly important.[1,3,5]

This review found that CBCT was the most frequently employed imaging technique, accounting for 8 out of the 13 included articles. This preference is primarily attributed to its

capacity to generate volumetric data of highly contrasted structures and Hounsfield Unit (HU) measurements, which reflect bone mineral density.[5,31] While CBCT does not provide standardized HU values comparable to medical CT, it offers a lower radiation dose. Its relative density values remain valuable for intra-patient comparisons and general presurgical assessment.[6] Consequently, CBCT is currently the most common tool used to evaluate bone quantity and quality in the maxilla and mandible during dental implant planning.[13] Despite these advantages, CBCT is not widely available in all dental clinics and is relatively expensive compared to other radiographic modalities, and it may be affected by noise, scatter, or cupping artifacts, potentially reducing measurement accuracy.[5,31]

Panoramic radiographs were utilized in four studies. This modality is commonly employed for preoperative radiographic examinations of edentulous patients and for morphological assessments before the placement of complete removable dental prostheses and endosteal dental implants.[31] Panoramic radiography provided a reasonable degree of accuracy in estimating bone density, particularly when combined with grayscale calibration or fractal analysis techniques. Although it has lower spatial resolution, panoramic imaging remains a cost-effective option for initial evaluations and has demonstrated acceptable correlation with implant stability indices.[9,22]

Periapical radiographs, although less frequently reported among the analyzed studies, were a common imaging tool for preoperative planning, evaluation, and minor oral surgical procedures. These radiographs offer high resolution and fine detail, surpassing extraoral radiographs, and present advantages of low radiation exposure, cost-effectiveness, and ease of use.[5,14,32,33] Moreover, these radiographs also facilitate the determination of alveolar bone height, the spatial relationship between the implant site and adjacent anatomical structures, and alveolar bone quality as indicated by the trabecular pattern surrounding the implant.[5]

Across the studies analyzed, bone density was consistently higher in the mandible than in the maxilla, and greater in anterior than posterior regions. This finding aligns with previous research demonstrating that the cortical bone of the anterior mandible is denser, contributing to initial implant stability. [26] These anatomical differences emphasize the need for individualized treatment planning that accounts for regional variations in bone density and quality.

Radiographic evaluation, despite its accessibility and non-invasive nature, has limitations in bone density assessment. The grayscale values obtained from CBCT scans are not universally standardized, varying based on equipment and acquisition parameters.[6] Additionally, metallic restorations or existing implants can introduce artifacts that distort density measurements.[34] The variety of methods and units used in studies to report bone density, including Hounsfield Units (HU), grayscale values (GV), grams per cubic centimeter (g/cm^3), and mmAleq, hinders direct comparison of findings. This underscores the need for standardized calibration and reporting protocols in radiographic bone assessment to facilitate meta-analyses and cross-study evaluation.

Considering the strong relationship between bone density and the favorable outcomes of dental implants, the systematic evaluation of bone quality utilizing suitable radiographic methods ought to be an integral aspect of presurgical preparation. CBCT is particularly recommended for detailed three-dimensional analysis, especially in cases involving complex anatomy or previous bone loss.

This scoping review has several limitations that warrant acknowledgment. First, heterogeneity in imaging protocols, measurement units, and reference points across studies posed challenges for direct comparison and synthesis of findings. Variations in CBCT acquisition parameters, calibration methods, and ROI definitions may have influenced bone density values, thereby limiting the generalizability of the results. Second, most included studies had relatively small sample sizes and were conducted in single-center settings, which may introduce selection bias and reduce external validity. Third, the review included studies with diverse methodologies—observational, retrospective, cross-sectional—which inherently differ in their capacity to establish causal relationships. Finally, although DEXA was identified as the gold standard for bone mineral density assessment, its application to alveolar bone was limited in the included literature, restricting robust comparisons between DEXA and dental radiographic modalities.

Future studies should focus on developing standardized ROI definitions, calibration procedures, and reporting formats for bone density in dental radiology. Additionally, longitudinal studies correlating radiographic bone density with clinical outcomes such as insertion torque, implant stability, and long-term survival are essential to strengthen the clinical relevance of radiographic assessment.

CONCLUSION

Radiographic evaluation of alveolar bone density is essential for effective dental implant planning, with CBCT emerging as the most utilized and informative modality. Evidence indicates that mandibular and anterior regions generally exhibit higher bone density, contributing to implant stability. However, variations in imaging protocols and measurement units, particularly within CBCT, pose challenges to data standardization. Despite these limitations, radiographic assessment remains a critical, non-invasive, and clinically valuable diagnostic tool. Implication of this scoping review highlight the need for standardized radiographic protocols and reporting systems in alveolar bone density evaluation. Such standardization will optimize presurgical implant planning, facilitate interstudy comparison, and ultimately improve clinical outcomes.

Author Contribution: "Conceptualization, F.P, R.R.A.J, R.I.D.; methodology, R.R.A.J, R.I.D; software, R.R.A.J, RID; validation, RRAJ, RID; formal analysis, RRAJ, RID; investigation, LHG, CPY, SH; resources, RRAJ, RID; data curation, LHG, CPY, SH; writing—original draft preparation, RRAJ, RID; writing—review and editing, RRAJ, RID; visualization, FP, DW, JAA; supervision, FP, DW, JAA, CS; project administration, RRAJ; funding acquisition, FP, DW, JAA. All authors have read and agreed to the published version of the manuscript."

Funding: The authors would like to thank Padjadjaran University for the financial support, through the RKDU Research Grant (Riset Kompetensi Dosen Unpad)

Informed Consent Statement: Informed consent was obtained from all subjects involved in the study Written informed consent has been obtained from the patient(s) to publish this paper

Data Availability: We encourage all authors whose articles are published in the journal Padjadjaran Journal of Dental Researchers and Students (PJDRS) to provide access to research data in accordance with the applicable research code of ethics.

Conflict of Interest: The authors declare no conflict of interest.

REFERENCES

1. Wang SH, Hsu JT, Fuh LJ, Peng SL, Huang HL, Tsai MT. New classification for bone type at dental implant sites: a dental computed tomography study. BMC Oral Health. 2023;23(324):1–13. https://doi.org/10.1186/s12903-023-03254-4
2. Lee JH, Yun JH, Kim YT. Deep learning to assess bone quality from panoramic radiographs: the feasibility of clinical application through comparison with an implant surgeon and cone-beam computed tomography. J Periodontal Implant Sci. 2024;54(5):349–58. https://doi.org/10.5051/jpis.2401190142
3. Prawoko SS, Nelwan LC, Odang RW, Kusdhany LS. Correlation between radiographic analysis of alveolar bone density around dental implant and resonance frequency of dental implant. J Phys Conf Ser. 2017;884:1–8. https://doi.org/10.1088/1742-6596/884/1/012127
4. Di Stefano DA, Arosio P, Capparè P, Barbon S, Gherlone EF. Stability of dental implants and thickness of cortical bone: clinical research and future perspectives—a systematic review. Materials. 2021;14(7183):1–21. https://doi.org/10.3390/ma14237183
5. Lubis RT, Azhari A, Pramanik F. Analysis of bone density and bone morphometry by periapical radiographs in dental implant osseointegration process. Int J Dent. 2023;1–9. https://doi.org/10.1155/2023/7139018
6. Wang SH, Fuh LJ, Chen MYC, Tsai MT, Huang HL, Peng SL, et al. Preoperative assessment of bone density for dental implantation: a comparative study of three different ROI methods. Head Face Med. 2024;20(33):1–11. https://doi.org/10.1186/s13005-024-00477-6
7. Issa NSH, Othman TA, Sleman BM. A comparative radiographic study of bone density changes around titanium implants in the posterior mandible, preoperative, and postoperative. Ann Med Surg. 2024;86:3216–21. https://doi.org/10.1016/j.amsu.2023.103216
8. Sahoo PK, Awinashe V, Bali Y, Gupta N, Parihar AS, Jagadeesh KN, et al. A cone-beam computed tomography evaluation of bone density for insertion of pterygoid implants in dentulous and edentulous patients. Tzu Chi Med J. 2022;34(1):82–7. https://doi.org/10.4103/tcmj.tcmj_5_21
9. Chugh NK, Bhattacharyya J, Das S, Ghosh S, Dutta K, Goel P. Use of digital panoramic radiology in presurgical implant treatment planning to accurately assess bone density. J Prosthet Dent. 2016;116(2):200–5.e1. https://doi.org/10.1016/j.prosdent.2016.01.017
10. Magat G, Ozcan Sener S. Evaluation of trabecular pattern of mandible using fractal dimension, bone area fraction, and gray scale value: comparison of cone-beam computed tomography and panoramic radiography. Oral Radiol. 2019;35:35–42. https://doi.org/10.1007/s11282-018-0316-1
11. Amri IM, Firman RN, Pramanik F. The correlation between age and mandibular bone quality based on panoramic radiographs. Makassar Dent J. 2021;10(3):204–8.

12. Eskandarloo A, Arabi R, Bidgoli M, Yousefi F, Poorolajal J. Association between marginal bone loss and bone quality at dental implant sites based on evidence from cone beam computed tomography and periapical radiographs. Contemp Clin Dent. 2019;10:36–41. https://doi.org/10.4103/ccd.ccd_444_18
13. Almasoud NN, Tanneru N, Marei HF. Alveolar bone density and its clinical implication in the placement of dental implants and orthodontic mini-implants. Saudi Med J. 2016;37(6):684–9. https://doi.org/10.15537/smj.2016.6.15032
14. Tayman MA, Sarıçam E. Fractal analysis of trabecular alveolar bone with intrabony and furcation defects using periapical dental radiographs. Eur J Ther. 2024;30(4):456–63. https://doi.org/10.58600/eurjther1651
15. Francisco I, Nunes C, Pereira F, Travassos R, Ribeiro MP, Marques F, et al. Bone Mineral Density through DEXA and CBCT: A Systematic Review with Meta-Analysis. Applied Sciences (Switzerland). 2023 May 1;13(10). https://doi.org/10.3390/app13105962
16. Slart RHJA, Punda M, Ali DS, Bazzocchi A, Bock O, Camacho P, et al. Updated practice guideline for dual-energy X-ray absorptiometry (DXA). Vol. 52, European Journal of Nuclear Medicine and Molecular Imaging. Springer; 2025. p. 539–63. https://doi.org/10.1007/s00259-024-06912-6
17. Sangondimath G, Sen RK, T FR. DEXA and Imaging in Osteoporosis. Vol. 57, Indian Journal of Orthopaedics. Springer; 2023. p. 82–93. https://doi.org/10.1007/s43465-023-01059-2
18. Al-fakeh H, Sharhan HM, Ziyad TA, Abdulghani EA, Al-Moraissi E, Al-Sosowa AA, et al. Three-dimensional radiographic assessment of bone changes around posterior dental implants at native bone site in Gansu Province, Northwest of China: a retrospective cohort study. J Stomatol Oral Maxillofac Surg. 2022;123:e186–91. https://doi.org/10.1016/j.jormas.2021.09.003
19. Jha S, Pathi J, Sangamesh NC, Singh DK, Sikdar A, Dash M. Marginal bone level and bone quality evaluation using CBCT after functional loading around dental implant in the population of Bhubaneswar, Odisha: a longitudinal study. J Pharm Res Int. 2022;34(21A):6–13. https://doi.org/10.9734/jpri/2022/v34i21A35847
20. Hayek E, Aoun G, Bassit R, Nasseh I. Correlating radiographic fractal analysis at implant recipient sites with primary implant stability: an in vivo preliminary study. Cureus. 2020;12(1):e6643. https://doi.org/10.7759/cureus.6643
21. Choi IGG, Pinhata-Baptista OH, Ferraço R, Kim JH, Abdala R, Arita ES, et al. Correlation among alveolar bone assessments provided by CBCT, micro-CT, and 14 T MRI. Dentomaxillofac Radiol. 2022;51:20210501. https://doi.org/10.1259/dmfr.20210501
22. Suer B, Yaman Z, Buyuksarac B. Correlation of fractal dimension values with implant insertion torque and resonance frequency values at implant recipient sites. Int J Oral Maxillofac Implants. 2016;31:55–62. https://doi.org/10.11607/jomi.3945
23. Oliveira MR, Gonçalves A, Gabrielli MAC, Pereira-Filho VA. Radiographic evaluation in the diagnosis of alveolar bone quality in implant rehabilitation. J Craniofac Surg. 2020;31(6):1805–8. https://doi.org/10.1097/SCS.0000000000006583
24. Poedjiastoeti W, Perwira Lubis MN, Ariesanti Y, Farizka I, Dipankara J, Inglam S. Alveolar bones density assessment of dental implant sites using cone-beam computed tomography. Padjadjaran J Dent. 2022;34(3):264–70. https://doi.org/10.24198/pjd.vol34no3.34260
25. Hayek E, Aoun G, Geha H, Nasseh I. Image-based bone density classification using fractal dimensions and histological analysis of implant recipient site. Acta Inform Med. 2020;28(4):272–7. https://doi.org/10.5455/aim.2020.28.272-277
26. de Elío Oliveros J, del Canto Díaz A, del Canto Díaz M, Orea CJ, del Canto Pingarrón M, Calvo JS. Alveolar bone density and width affect primary implant stability. J Oral Implantol. 2020;46(4):389–95. https://doi.org/10.1563/aaid-joi-D-19-00067
27. Harper KD, Clyburn TA, Incavo SJ, Lambert BS. DEXA overestimates bone mineral density in adults with knee replacements. Sports Med Health Sci. 2020;2(4):211–5. https://doi.org/10.1016/j.smhs.2020.10.004
28. Martin-Monge E, Tresguerres I, Clemente C, Tresguerres J. Local application of growth hormone to enhance osseointegration in osteoporotic bones: a morphometric and densitometric study. Int J Oral Maxillofac Implants. 2017;32(4):751–8. https://doi.org/10.11607/jomi.5801
29. Hansen RL, Langdahl BL, Jørgensen PH, Petersen KK, Søballe K, Stilling M. Bone mineral density measurements around osseointegrated implants: a precision study and validation of scan protocol for transfemoral amputees. J Clin Densitom. 2018;21(2):244–51. https://doi.org/10.1016/j.jocd.2017.02.006
30. Merheb J, Temmerman A, Rasmusson L, Kübler A, Thor A, Quirynen M. Influence of skeletal and local bone density on dental implant stability in patients with osteoporosis. Clin Implant Dent Relat Res. 2016;18(2):253–60. https://doi.org/10.1111/cid.12281
31. Ayob M, Md Jasin J, Suparman M, Reduwan N. Comparison between digital panoramic radiography and cone-beam computed tomography in measuring presurgical dental implant vertical height at posterior mandible. Compend Oral Sci. 2022;9(1):8–14.
32. Oohashi M, Mizuhashi F, Sugawara Y, Saegusa H, Katsumata A, Ogura I. Computer assisted measurement of radiographical alveolar bone density using intraoral radiographs: preliminary study on comparison between men and women in young adults. J Oral Maxillofac Radiol. 2020;8:1–4. https://doi.org/10.4103/jomr.jomr_53_20
33. Katsumata A, Kohinata K, Esaki Y, Kawai M. Variance of radiographical alveolar bone mineral density by the anatomical morphology of mandibular bone. Heliyon. 2022;8:e11507. https://doi.org/10.1016/j.heliyon.2022.e11507
34. Silveira-Neto N, Flores ME, de Carli JP, Costa MD, Matos F de S, Paranhos LR, et al. Peri-implant assessment via cone beam computed tomography and digital periapical radiography: an ex vivo study. Clinics. 2017;72(11):708–13. https://doi.org/10.6061/clinics/2017(11)09